

# Congenital absence of the incus bilaterally without other otologic anomalies: A new case report

Reza Rahbar, DMD, MD

Marilyn W. Neault, PhD

Margaret A. Kenna, MD

## Abstract

*We describe only the third reported case of congenital, bilaterally absent incuses that were not accompanied by another otologic abnormality. This condition was detected in a 3-year-old boy who was being evaluated for a hearing impairment and speech and language delay. The patient was treated with partial ossicular replacement prostheses, which resulted in an improvement in his hearing.*

## Introduction

A congenital absence of the incus bilaterally without other otologic manifestations is an uncommon clinical entity. During the past 40 years, only two such cases have been reported.<sup>1,2</sup> In this article, we report the third such case, which was detected in a young boy during an evaluation of a hearing impairment and speech and language delay.

## Case report

A 3-year-old boy was referred to our outpatient otolaryngology clinic for evaluation of diminished hearing and a significant speech and language delay. At that time, his mother reported that he spoke in short, unintelligible phrases. His prenatal and birth history was normal, and he had no significant history of otitis media. His family history was significant for speech delay in a paternal uncle and a first cousin, but neither of the boy's two brothers had any hearing or speech and language abnormalities. Nei-

ther clinical otoscopy nor the remainder of the otolaryngologic examinations revealed any abnormalities. Play audiometry demonstrated a moderately severe conductive hearing loss bilaterally. The tympanogram was normal.

For further evaluation, computed tomography (CT) of the temporal bone was obtained, and findings were reported as normal. Treatment options, including hearing aids and a middle ear exploration for evaluation of ossicular change, were discussed. Per the family's request, the patient was referred for hearing-aid fitting and placed in a special-needs program at school, where he underwent daily speech and language therapy.

An audiometric reevaluation when the boy was 4 years old confirmed the moderately severe conductive hearing loss (figure 1). After a number of consultations with the family, the decision was made to perform a middle ear exploration to rule out any middle ear or ossicular abnormality that might be contributing to the hearing loss. The patient underwent a right middle ear exploration via a transcanal approach. The tympanomeatal flap was elevated, and an atticotomy was created to allow for better examination of the stapes. The malleus and stapes were found to be normal and mobile on palpation, but there was a complete ossicular-chain discontinuity because the incus was absent. The remainder of the middle ear anatomy was unremarkable.

A right ossiculoplasty was performed, and a partial ossicular replacement prosthesis (PORP) was placed in the area from the stapes superstructure to the malleus. One month postoperatively, audiometry revealed a reduction of the air-bone gap on the right (figure 2). Six months later, the patient underwent a left middle ear exploration, which also revealed an absence of the incus and a normal and mobile malleus and stapes. Again, a PORP was placed in the area from the stapes superstructure to the malleus. Two months postoperatively, audiometry revealed a 40-dB improvement on the left (figure 2).

From the Departments of Otolaryngology and Communication Disorders, Children's Hospital, Boston, and the Department of Otolaryngology and Laryngology, Harvard Medical School, Boston.

Reprint requests: Reza Rahbar, DMD, MD, Department of Otolaryngology, Children's Hospital, 300 Longwood Ave., Boston, MA 02115. Phone: (617) 355-8859; fax: (617) 277-2497; e-mail: reza.rahbar@tch.harvard.edu

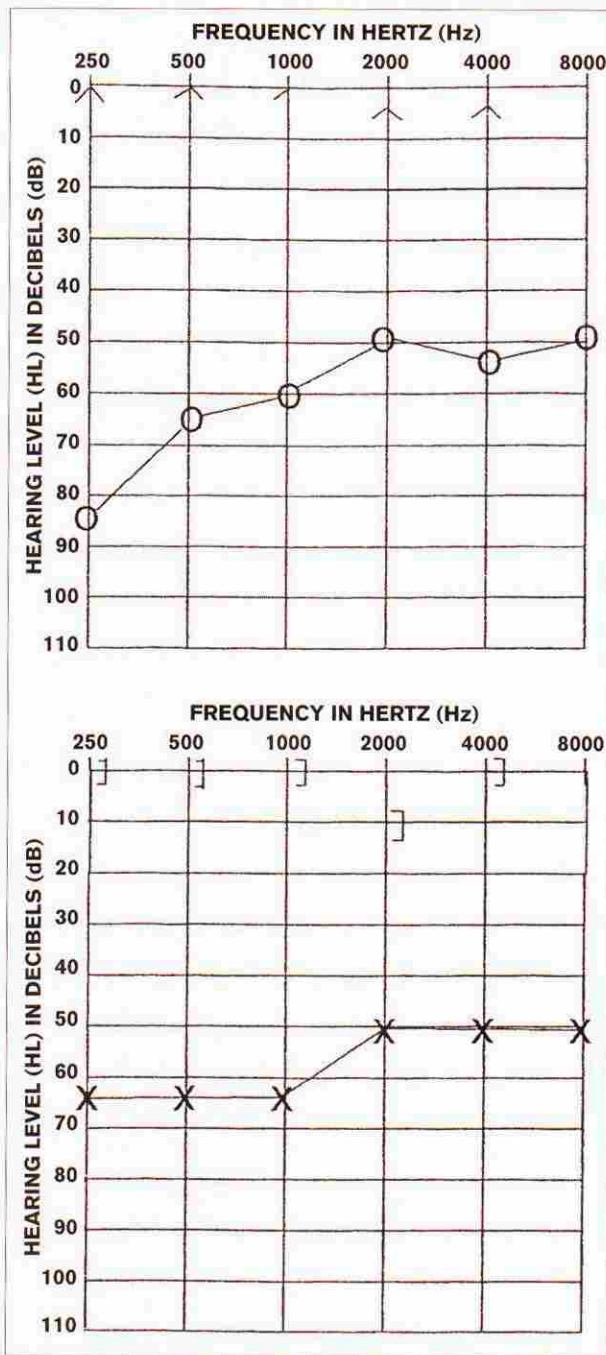


Figure 1. Preoperative audiometry reflects the moderately severe conductive hearing loss.

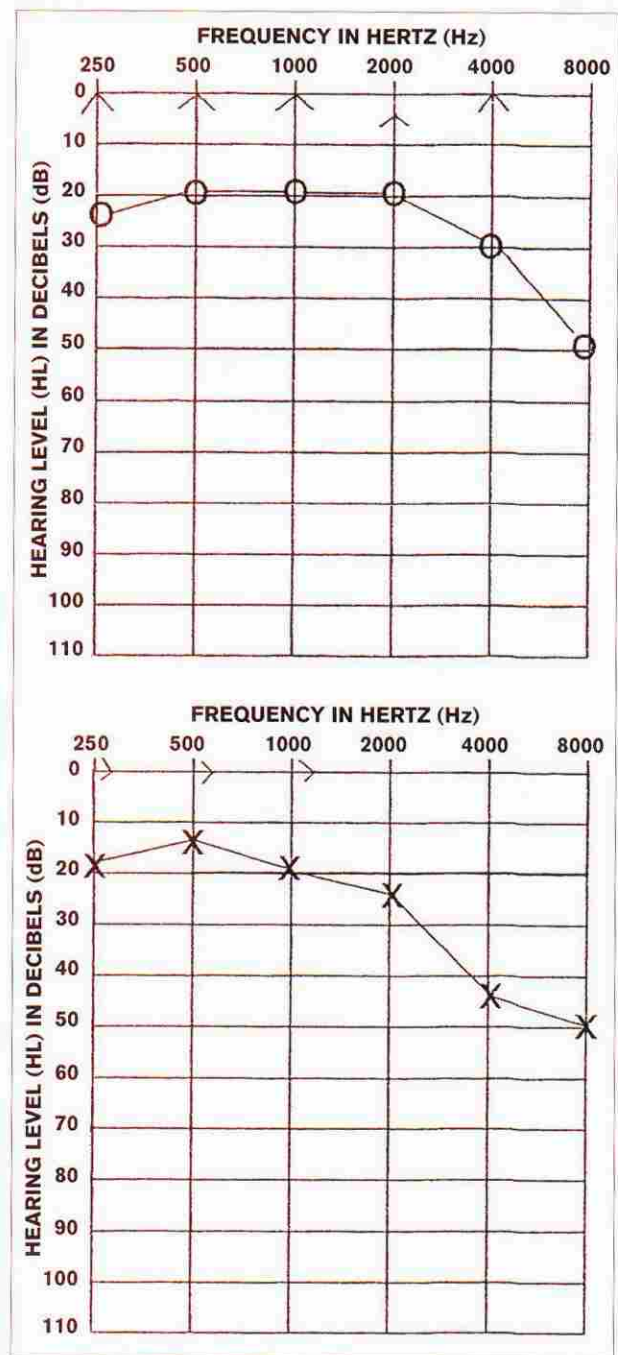


Figure 2. Postoperative audiometry shows improvement in both ears.

**Discussion**

Most cases of congenital hearing loss in the pediatric population are sensorineural in origin. Cases of congenital or hereditary conductive hearing loss are rare.<sup>3</sup> There are two types of congenital conductive hearing loss; one is associated with microtia and external auditory canal atresia, and the other occurs in patients whose external ear anatomy is normal. In the latter case, hearing loss can be caused by conditions such as osteogenesis imperfecta,

branchio-oto-renal syndrome, orofaciodigital type II syndrome, and Treacher Collins syndrome.<sup>3</sup>

Funasaka et al first applied a formal classification system to cases of isolated ossicular abnormality.<sup>4</sup> They classified these abnormalities as type I (malleus or incus fixation), type II (incudostapedial disconnection), and type III (stapes fixation). These abnormalities can occur singly or in combination. Isolated ossicular abnormalities that occur in the absence of other anomalies are rare.

For many years during the first half of the 20<sup>th</sup> century, it was well accepted that the middle ear develops primarily from the first and second branchial arches and that the ossicles are derived from various contributions by Meckel's cartilage, Reichert's cartilage, and the otic capsule. Under this hypothesis, (1) Meckel's cartilage was solely responsible for the head and neck of the malleus, and the body and short process of the incus; (2) Reichert's cartilage was responsible for the handle of the malleus, the long process of the incus, the crura, and the lateral stapedial footplate; and (3) the otic capsule was responsible for the medial stapedial footplate.

However, in the late 1950s and early '60s, Hough began to challenge these premises, and he proposed that "no two ears are alike, and each ear is as different as each human face."<sup>5-8</sup> Hough suggested that the malleus and the incus are each derived from separate populations of mesenchymal cells.<sup>5,7</sup> He put forth the notion that not every middle ear conforms to the territorial confines of Reichert's and Meckel's cartilage. In fact, a case such as the one we describe here could be explained only by the derivation of each ossicle from separate populations or islands of mesenchymal cells. Similarly, Bowden suggested a role for differential resorption and/or pathogenic resorption of middle ear cartilaginous and bony structures by invading endoderm or by endodermal-mesodermal junctional tissue.<sup>9</sup>

In a review of middle ear abnormalities reported prior to 1960, Henner found no record of a congenitally absent incus that was not accompanied by some other abnormality.<sup>10</sup> Our own review of the literature published since 1966 yielded only two such cases.<sup>1,2</sup> It is interesting that both of those cases and the one we report here involved a congenitally absent incus bilaterally, with an essentially normal malleus and either a normal or only mildly malformed stapes.

We are fully aware that there are two inconsistencies in this case. First, we reported that the patient's tympanogram was normal. In fact, in a patient with a missing incus and ossicular discontinuity, the tympanogram should have revealed an axis-deviation curve. Although a tympanogram can reflect the mobility of the most peripheral portion of the middle ear system, the finding in our case was probably the result of a technical error.

Second, we reported that findings on the 3-mm, axial-cut, temporal bone CT were also normal. However, a closer review of the CT image indicated that the ossicular discontinuity was indeed present. Considering the currently accepted theory that explains the relative contributions of the first and second branchial arches to ossicular formation, there is no straightforward explanation for the development of such anomalous anatomic variations. Clearly, further research is needed to reevaluate potential etiologies for an isolated absent incus.

A thorough discussion of ossicular reconstructive techniques is beyond the scope of this article. In brief, the goal of surgery in these cases is to produce a functional sound-transformer mechanism.<sup>1</sup> The use of various prostheses has been well described. It should be emphasized that reconstruction should be deferred until the patient is beyond the period of high risk for otitis media, to avoid unnecessary postoperative complications associated with infection.

Congenital ossicular deformity might be underappreciated in pediatric patients, in whom conductive hearing loss is generally caused by otitis media and middle ear effusion. Several features that should raise the level of suspicion for congenital hearing loss are a history of conductive hearing loss since birth, a degree of hearing loss that is greater than would be expected with middle ear infection or effusion, a persistence of hearing loss after ventilation tube placement, the presence of other anomalies, and a family history of hearing problems. Proper and timely diagnosis is essential to the management of these patients. Our experience and literature review indicate that long-term restoration of the sound-transformer mechanism and functional hearing can be achieved successfully and safely.

## References

1. Shea JJ III, Shea JJ, Jr., Orchik DJ, Emmett JR. Congenital absence of the incus: A novel method of reconstruction. *Otolaryngol Head Neck Surg* 1987;97:413-5.
2. Soh KB, Tan KK. Congenital absence of incus—a rare abnormality. *Ann Acad Med Singapore* 1995;24:333-5.
3. Higashi K, Yamakawa K, Itani O, Togawa K. Familial ossicular malformations: Case report and review of literature. *Am J Med Genet* 1987;28:655-9.
4. Funasaka S, Abe H, Tozuka G, Tokumasu K. Anomalies of the ossicles without malformations of the external ear. *Otologia (Fukuoka)* 1971;17:250-7.
5. Hough JVD. Malformations and anatomical variations seen in the middle ear during operations on the stapes: A manual prepared for the use of graduates in medicine. American Academy of Ophthalmology and Otolaryngology, 1961.
6. Hough JVD. Malformations and anatomical variations seen in the middle ear during the operation for mobilization of the stapes. *Laryngoscope* 1958;68:1337-79.
7. Hough JVD. Congenital malformations of the middle ear. *Arch Otolaryngol* 1963;78:355-43.
8. Hough JVD. Incudostapedial joint separation: Etiology, treatment and significance. *Laryngoscope* 1959;69:1337-79.
9. Bowden RE. Development of the middle and external ear in man. *Proc R Soc Med* 1977;70:807-15.
10. Henner R. Congenital middle ear malformation. *Arch Otolaryngol* 1960;71:454-8.