

Creation of an Atrial Septal Defect In Utero for Fetuses With Hypoplastic Left Heart Syndrome and Intact or Highly Restrictive Atrial Septum

Audrey C. Marshall, MD; Mary E. van der Velde, MD; Wayne Tworetzky, MD; Carlen A. Gomez, MD; Louise Wilkins-Haug, MD, PhD; Carol B. Benson, MD; Russell W. Jennings, MD; James E. Lock, MD

Background—Infants born with hypoplastic left heart syndrome and an intact or highly restrictive atrial septum face a neonatal mortality of at least 48% despite early postnatal left atrial decompression and palliative surgery. Prenatal left atrial decompression has been suggested as a means of improving these outcomes. This study reports the feasibility of fetal catheterization to create an interatrial communication and describes technical considerations.

Methods and Results—Seven fetuses at 26 to 34 weeks' gestation with hypoplastic left heart syndrome and intact or highly restrictive atrial septum underwent attempted prenatal intervention. Under ultrasound guidance, the atrial septum was approached with a needle introduced percutaneously from the maternal abdominal surface. In 6 of 7 fetuses, the atrial septum was successfully perforated, with balloon dilation of this iatrogenic defect resulting in a small but persistent interatrial communication. There were no maternal complications. One fetus died after the procedure. The remaining fetuses were liveborn at term, although 4 died as neonates.

Conclusions—Ultrasound-guided fetal atrial septoplasty consisting of septal puncture and balloon dilation is feasible and can be performed percutaneously to minimize maternal risk. Although we have not demonstrated any positive clinical impact to date, it is our hope that further technical evolution will ultimately enable prenatal left atrial decompression and improvement of outcomes in fetuses with hypoplastic left heart syndrome and intact atrial septum. (*Circulation*. 2004;110:253-258.)

Key Words: catheterization ■ heart defects, congenital ■ pregnancy

Despite improved operative survival for infants born with hypoplastic left heart syndrome (HLHS), one form of the disease continues to carry a particularly high mortality rate: HLHS with an intact or highly restrictive atrial septum (IAS). The incidence of intact atrial septum in the setting of HLHS has been estimated at 6%, with some degree of atrial septal restriction occurring in up to 22% of cases.¹⁻³ These neonates develop profound cyanosis and pulmonary edema immediately after delivery. Standard resuscitative measures are often unsuccessful. Given the ineffectiveness of medical stabilization, some centers have performed emergent Norwood procedures to relieve the severe cyanosis. The largest series of patients with HLHS managed in this fashion suffered a 6-month mortality of 83%.¹ Even among neonates undergoing early transcatheter procedures to relieve atrial septal obstruction, the neonatal mortality is 48%.^{4,5}

Of note, much of the mortality in patients with HLHS and IAS occurs after the first week of life, when the purely

technical challenges of opening the septum and maintaining oxygenation have been overcome. This ongoing mortality may be due in part to associated intrapulmonary anatomic abnormalities. Pathological series by Haworth and Reid^{6,7} first described postnatal anatomic lung abnormalities associated with altered fetal pulmonary flow patterns. Several groups have subsequently described pulmonary abnormalities, including "arterialization" of the pulmonary veins and lymphatic dilation, in patients with HLHS and IAS and have attributed these findings to left atrial (LA) hypertension in utero.^{1,8,9}

If prenatal LA hypertension results in secondary anatomic changes in the lung and thereby contributes to poor postnatal outcomes, then the best form of management of HLHS with IAS should incorporate decompression of the fetal LA. On the basis of this hypothesis, we sought to develop a procedure for atrial septal defect creation in utero. Our approach to this procedure drew on published experience with fetal cardiocen-

Received September 30, 2003; de novo received December 16, 2003; revision received March 25, 2004; accepted March 26, 2004.

From the Departments of Cardiology, Children's Hospital, and Pediatrics, Harvard Medical School, Boston, Mass (A.C.M., W.T., J.E.L.); Division of Pediatric Cardiology, C.S. Mott Children's Hospital, Ann Arbor, Mich (M.E.v.d.V., C.A.G.); Departments of Obstetrics and Gynecology (L.W.-H.) and Radiology (C.B.B.), Brigham and Women's Hospital and Harvard Medical School, Boston, Mass; and Department of Surgery, Children's Hospital and Harvard Medical School, Boston, Mass (R.W.J.).

Correspondence to Audrey C. Marshall, MD, Department of Cardiology, Children's Hospital, 300 Longwood Ave, Boston, MA 02115. E-mail Audrey.marshall@cardio.chboston.org

© 2004 American Heart Association, Inc.

Circulation is available at <http://www.circulationaha.org>

DOI: 10.1161/01.CIR.0000135471.17922.17

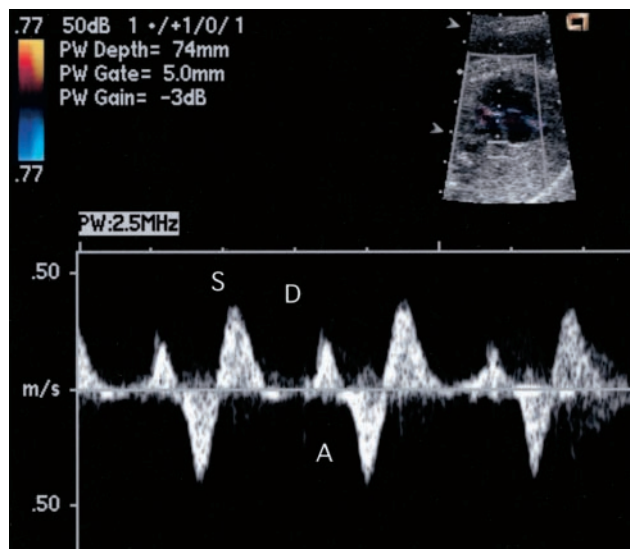


Figure 1. Pulmonary venous flow Doppler in fetus with intact atrial septum demonstrating flow reversal. S wave represents antegrade flow in pulmonary vein during ventricular systole; D wave, additional antegrade flow in diastole; and A wave, retrograde flow in pulmonary vein during atrial contraction.

tesis and aortic valve dilation and on our own experience with fetal aortic valvuloplasty.^{10,11} We also incorporated transcatheter techniques similar to those successfully used to achieve postnatal LA decompression in the neonate.^{4,12} This report describes the technical progress made thus far toward a transcatheter intervention to relieve LA hypertension in the fetus with HLHS and IAS.

Methods

Seven pregnant women who underwent fetal echocardiography at our institution between September 2002 and November 2003 were offered prenatal intervention to open an intact ($n=4$) or highly restrictive ($n=3$) atrial septum. All fetuses were diagnosed with HLHS through the use of standard fetal echocardiographic techniques and criteria. Prominent flow reversal in dilated pulmonary veins indicated LA hypertension in all 7 fetuses despite the presence of small decompressing veins in 2 (Figure 1).^{13,14} Two fetuses were hydroptic at diagnosis. Three of the fetuses had a small LA with a thick atrial septum, whereas the others had a thin septum bowing into the right atrium.

Fetal Intervention

Procedures were performed between 26 and 34 weeks' gestation, with maternal and fetal anesthesia provided according to previously described techniques.¹⁵ On the basis of known effects of inhalational anesthetics for both fetal procedures and nonemergent laparotomy in the second trimester, we used general anesthesia to maximize uterine

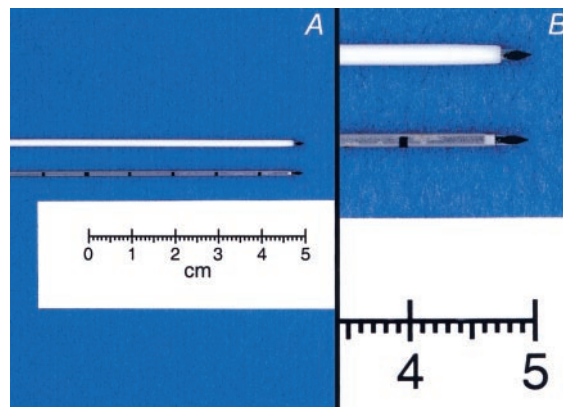


Figure 2. A, B, Percutaneous introducers used for fetal atrial septoplasty. The 18-gauge instrument is above (B); 19-gauge instrument is below (A). At higher magnification (B), one can appreciate blunt shoulder of both introducers and similarity of diamond-shaped obturators.

relaxation and control fetal position.^{15,16} In 2 cases, when fetal position appeared nearly ideal before maternal induction, we elected to perform the procedure under spinal anesthesia with intravenous sedation. Using transabdominal ultrasound imaging, we identified an unobstructed line of approach from the anterior maternal abdomen to the fetal right atrium, through the LA, and into a left pulmonary vein. The fetuses were then given intramuscular narcotics and muscle relaxants. In 1 case, anesthetic was delivered via the umbilical vein to a hydroptic fetus.

An 18- or 19-gauge introducer cannula mounted on a sharp metal obturator (Cook Inc) was percutaneously advanced into the uterus, through the fetal chest wall, and to the right atrial epicardial surface. The stainless steel 19-gauge cannula (used in 6 fetuses) had an OD of 0.0465 in, whereas the 18-gauge cannula (used in 1 fetus) had a plastic shaft with an OD of 0.060 in (Figure 2). The obturator of both instruments had a diamond-shaped tip leading the blunt shoulder of the cannula by 2.5 mm.

Following the previously identified line of approach, the introducer was advanced into the right atrium and positioned against the atrial septum. In some instances, the septum was punctured by briskly advancing the tip of the introducer itself. More commonly, the atrial septum was punctured with a 22-gauge Chiba needle (Cook Inc) placed through the introducer after removal of the obturator (Figure 3). Through the Chiba needle, a 0.014-in wire (Cordis) was introduced into the LA or a pulmonary vein. Over this wire, the Chiba needle was exchanged for a balloon angioplasty catheter (Cordis). This catheter was advanced through the introducer cannula into the LA. By premeasuring and marking the shafts of the balloon catheters, we could infer the position of the balloon through visualization of the cannula in the right atrium and the wire in the left pulmonary vein (Figure 4).

Because of the luminal constraints of the introducers, the largest balloons used had a nominal diameter of 3.0 mm. Inflation was carried out at 15 atm to take advantage of the maximal inflated diameter achievable in these relatively noncompliant balloons. The

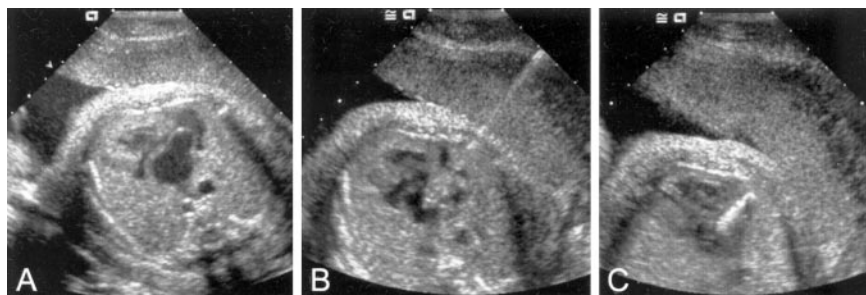


Figure 3. A–C, Transabdominal ultrasound image of heart in 1 fetus with dilated left atrium and thin, bulging atrial septum before atrial septal puncture (A), during septal puncture with Chiba needle (B), and during dilation with 3-mm coronary angioplasty balloon (C).

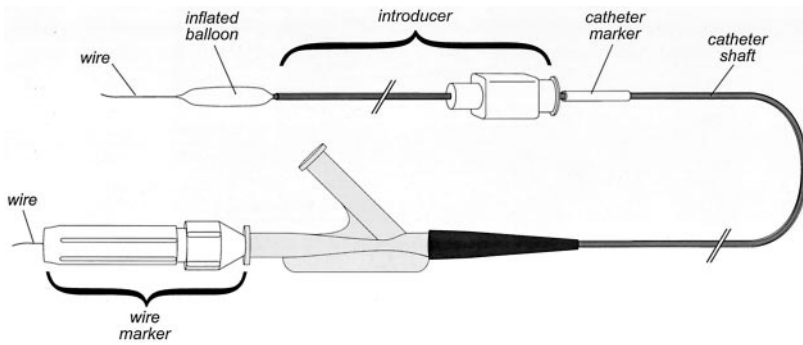


Figure 4. System for premeasuring and marking catheter. In preparation for procedure, balloon catheter is mounted coaxially on 0.014-in wire. Wire is marked so that ≈ 2 cm of wire extends beyond catheter tip. Catheter shaft is advanced through introducer cannula until entire balloon is exposed. Low-profile, opaque white cuff, 1 cm in length, is affixed to catheter shaft so that this cuff can be seen and felt abutting introducer hub.

balloon was fully inflated twice before removal of the wire from the LA. In some cases, >1 puncture of the atrial septum was attempted through a single right atrial entry site.

A technically successful procedure was defined as one in which passage and inflation of a balloon catheter across the atrial septum were documented by echocardiography and flow was subsequently detected across a new atrial septal defect. After removal of the instruments, the atrial septum was briefly reimaged in the operating room. It was examined more completely before hospital discharge and was restudied approximately every 2 to 4 weeks through the remainder of gestation.

Informed Consent

This study was performed in accordance with the innovative therapy guidelines of the Committee on Clinical Investigation at the Children's Hospital Boston and the Institutional Review Board at the Brigham and Women's Hospital. In every case, maternal and fetal risks were discussed with the subjects by a fetal cardiologist, a perinatologist, a fetal surgeon, and an anesthesiologist.

Results

Technical success was achieved in 6 of 7 cases (the Table, fetuses 1 through 5 and 7). The elapsed time from percutaneous entry of the abdomen to catheter removal ranged from 18 to 44 minutes. One procedure, attempted under spinal anesthesia, was unsuccessful (Table, fetus 6). Persistent uterine tone, limiting our ability to manipulate the fetus, resulted in imperfect position and an inability to maintain an ideal line of approach. Additional factors, including a large maternal habitus, an anterior placenta, and anteriorly flexed fetal arms, further impaired imaging and positioning. After a single attempt at cardiac puncture, the procedure was terminated without evidence of LA entry.

One fetus (the Table, fetus 3) died within 4 hours of the procedure, and labor was induced. Postmortem examination of this fetus revealed puncture sites in the thickened right atrial free wall and overlying pericardium, with a large (9 mL) right hemothorax and a small (1 mL) hemopericardium. This fetus was the only one instrumented with the 18-gauge cannula. None of the fetuses exhibited bradycardia requiring resuscitation or developed more than a small pericardial effusion. None of the mothers experienced any procedural complication.

The size of the newly created atrial defect was determined at postmortem examination in the fetus who died and by fetal echocardiography in the remaining fetuses (Table). The autopsy revealed a tiny (0.25 mm) defect in the thick atrial septum. Four fetuses had evidence of new atrial septal defect measuring >2 mm in diameter after technically successful intervention (Figure 5). One fetus had only a tiny defect by imaging despite a technically successful procedure. Pulmonary venous flow patterns were reassessed in all the fetuses who survived intervention and continued to exhibit flow reversal. The echocardiographic appearance of the atrial defects remained unchanged through the remainder of gestation.

Six fetuses survived to delivery at or near term. The neonate who had failed prenatal intervention underwent a postnatal catheterization for LA decompression and subsequently survived Norwood stage I. Three neonates who had undergone technically successful fetal interventions also underwent postnatal catheterization for LA decompression and survived to a Norwood procedure. Fetus 1 completed an uneventful stage I palliation at 2 days of life, followed by

Summary of Procedures

Fetus	Gestational Age, wk	LA Size, mm	Septum	LA-RA Gradient, mm Hg	Balloon Diameter, mm	Result*	O ₂ Saturation at Catheterization, %	LA Pressure, mm Hg	Outcome
1	34	20×22	Thin	$\geq 9\ddagger$	3.0	++	73	33	Alive
2	30	8×10	Thick	$\geq 7\ddagger$	2.75	+	58	28	Neonatal death
3‡	26	5×7	Thick	Intact	2.75	+	NA	NA	Fetal demise
4	26	8×10	Thin	8	3.0	++	NA	NA	Neonatal death
5‡	30	27×37	Thin	Intact	2.75	++	NA	NA	Neonatal death
6	29	6×15	Thick	Intact	NA	0	43		Alive
7	33	11×15	Thin	Intact	2.75	++	61	26	Neonatal death

RA indicates right atrium.

*Results are the following: 0, no new defect; +, new defect ≤ 1 mm; and ++, new defect >2 mm.

‡Determined by interrogating decompressing vein.

‡Hydropic.

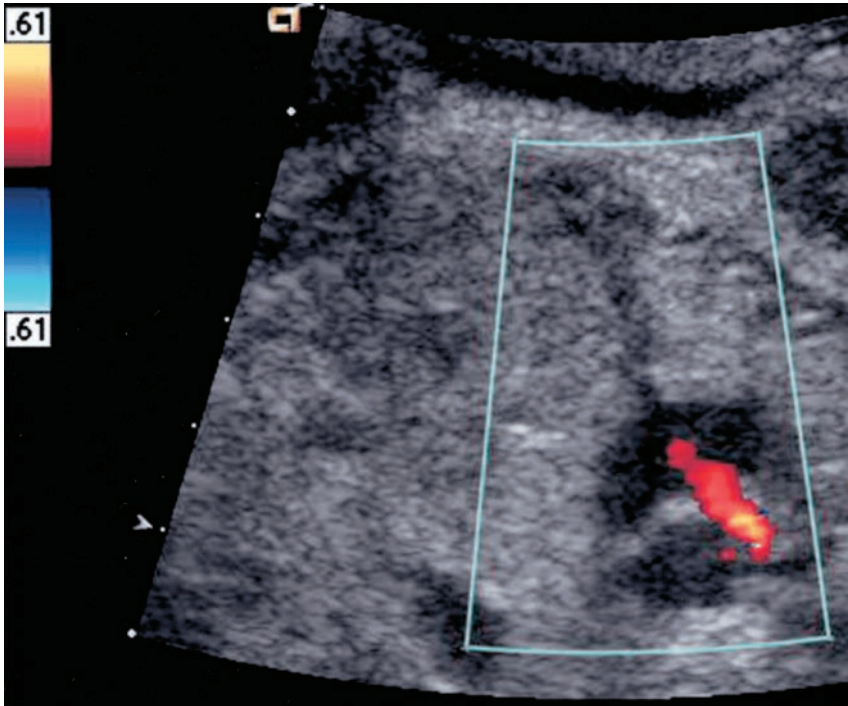


Figure 5. Ultrasound image with color Doppler showing transseptal flow through newly created 2.5-mm atrial septal defect.

bidirectional Glenn at 5 months. Fetuses 2 and 7 had prolonged postoperative courses after stage I and died of multisystem organ failure. In the course of management of fetus 2, a CT of the chest was performed and revealed macrocystic replacement of the entire left lung (Figure 6). One neonate (fetus 4) was managed with early stage I rather than catheter-directed LA decompression. Despite early postoperative difficulties requiring surgical revision, the infant was convalescing on a ward when a sudden cardiac arrest resulted in death. The final neonate (fetus 5), hydropic before

intervention at 30 weeks' gestation, was delivered at 34 weeks because of fetal distress. The infant had massive ascites and was unable to be ventilated, and resuscitation was discontinued after discussion with the parents. Postmortem examinations were available for only 2 of the infants in this series, and microscopic lung pathology was not reported.

Discussion

Staged surgical palliation of HLHS to a Fontan circulation continues to result in improved outcomes for infants born

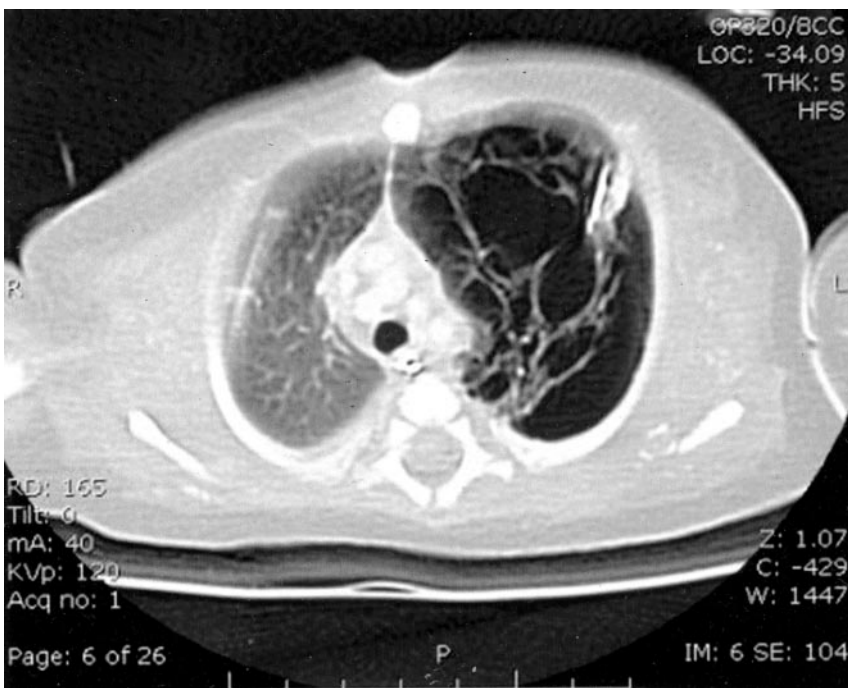


Figure 6. Axial cut image from chest CT showing macrocystic changes of left lung consistent with unilateral pulmonary emphysema.

with this disease. However, the presence of an intact or nearly intact atrial septum distinguishes a distinct, high-risk subset of infants despite prenatal diagnosis and early postnatal intervention.^{2,17} Neonates with HLHS and IAS are often unstable shortly after birth, with progressive cyanosis and pulmonary edema unresponsive to standard medical resuscitation. Even after initial stabilization, this subgroup remains at high risk regardless of whether staged surgical palliation or heart transplant is pursued.^{18,19} We and others have speculated that secondary developmental abnormalities of the lung may contribute to the high mortality observed in these infants.^{1,5,9}

For these infants, creation of an atrial septal defect in utero offers 2 potential benefits. In the short term, establishment of a decompressing atrial septal defect prenatally may improve postnatal pulmonary venous runoff, thereby resulting in a more stable infant in the first few hours of life. Over the longer term, fetal LA decompression may attenuate secondary anatomic changes in the lungs, allow time for beneficial pulmonary remodeling in utero, and mitigate unfavorable hemodynamic effects in the palliated single-ventricle patient.

On the basis of our accumulating experience with fetal aortic valve dilation, we set out to design a new procedure for fetal atrial septoplasty and offered prenatal intervention to achieve fetal LA decompression in 7 high-risk pregnancies. The technique was similar to that used for postnatal atrial septoplasty in the neonate with HLHS and IAS.^{4,12} The equipment used was identical to that used for percutaneous fetal aortic valve dilation.

The technique and tools described achieved technical success in 6 of 7 cases. Our only technical failure occurred in a case in which spinal rather than general anesthesia was used. In this case, persistent uterine tone contributed to suboptimal positioning. As a result, our line of approach was poor, and we were unable to enter the LA. Given the absence of maternal morbidity in our experience and the critical importance of fetal positioning for a successful procedure, we believe that our experience supports the continued use of general anesthesia for these procedures.

Despite our high rate of technical success, we were only able to create an atrial defect of >2 mm in 4 fetuses. We attributed the small size of these defects to a number of factors. It was certainly related to the size of the introducer we used. The profiles of available angioplasty balloons dictated that the largest balloon we could deliver to the atrial septum through the introducer was ≈ 3 mm. After we found only a tiny defect in the septum of fetus 2, we attempted dilation with a larger balloon, and therefore a larger introducer, in the third case. The 42% increase in the OD of this introducer and the corresponding doubling of the circumferential area resulted in difficulty in traversing the fetal chest wall and myocardium. Traumatic injury inflicted by this larger introducer presumably led to early postprocedural demise. We have subsequently used only the 19-gauge introducer to minimize the risk associated with fetal cardiac puncture. Delivery of larger effective dilating diameters will likely require development of lower-profile catheters than are currently available.

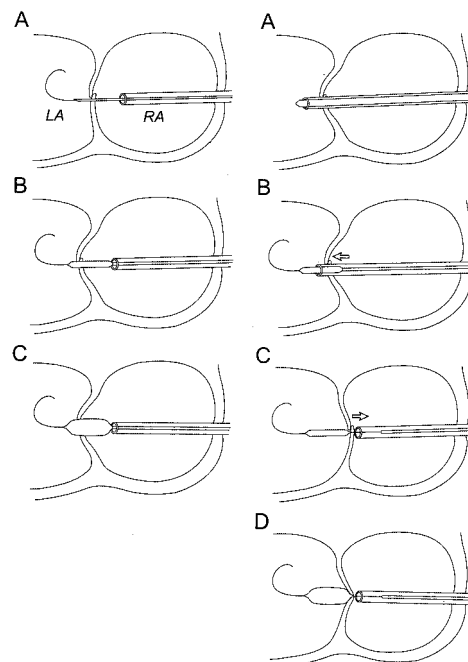


Figure 7. Proposed mechanism of septal malposition before dilation. Left, Chiba needle technique. A, With introducer in right atrium (RA), Chiba needle is used to puncture septum, and guidewire is advanced into LA. B, Chiba needle is exchanged for dilating balloon over this wire. C, Visualization of distal wire and introducer in right atrium confirms straddling of septum before balloon inflation. Right, Without use of Chiba needle. A, Introducer and obturator are advanced fully into LA. B, On removal of obturator, wire and balloon are advanced together through introducer into LA. Septum remains displaced into LA (arrow). C, Withdrawal of introducer to right atrium to uncover balloon results in septal “drag” and malposition (arrow). D, Entire balloon remains on LA side of septum during inflation.

We also considered the possibility that balloon malposition occurred, resulting in failure to dilate the atrial septal puncture site. When ultrasound imaging of the septum was not definitive, we relied on a system of premeasurement to confirm correct balloon position before inflation. With this system, relative “protection” of the atrial septum could theoretically occur if the introducer tip was leftward of the septum at the time of balloon inflation. In cases in which the septum was directly punctured with the introducer, a thick septum might be drawn rightward with the introducer before balloon placement (Figure 7). Although use of the Chiba needle technique should have decreased the likelihood of this septal distortion, we could not confirm that this technique did in fact produce larger septal defects.

Finally, it is likely that our failure to create larger defects despite the use of 3-mm dilating balloons was due in part to septal recoil after balloon deflation. We observed that all defects >2 mm were seen in fetuses with a thin atrial septum, suggesting that greater recoil of thicker septa may make them relatively unresponsive to static dilation. As with postnatal LA decompression procedures, stent placement may be necessary to maintain an adequate atrial septal defect.⁴ Alternative techniques, such as creation of multiple fenestrations, use of cutting instruments, or local excision of septal tissue, may also be prove useful, particularly in fetuses with thick atrial septa.

The primary aims of this study were to establish the feasibility of and to describe techniques for prenatal intervention to create an interatrial communication in HLHS with IAS. We do not as yet have evidence of clinical impact. Despite the echocardiographic appearance of new atrial defects, we did not observe any indication of physiological change; pulmonary venous flow reversal persisted in all cases. Furthermore, the overall mortality among the fetuses and infants described in our series remained high. Understanding of the physiological impact of fetal atrial septoplasty will require systematic assessment of pulmonary arterial, as well as venous, flow patterns and the degree of atrial septal restriction. Appreciating the nature and extent of associated pulmonary abnormalities will also be useful in assessing the effect of this procedure. With continued technical evolution and a greater understanding of physiological effects, we hope to ultimately demonstrate favorable clinical impact of in utero LA decompression for fetuses with HLHS and IAS.

Conclusions

We report the feasibility of percutaneous prenatal intervention to create an interatrial communication in fetuses with HLHS with IAS, with a high rate of technical success and no maternal morbidity, in a small number of patients. This small series does not attempt to demonstrate the clinical impact of this procedure, and many issues surrounding the potential effects of the procedure remain poorly understood. Specific physiological and anatomic effects will be the focus of future inquiry. Critical issues such as patient selection and timing of the procedure also require additional investigation. Nonetheless, the degree of technical success we experienced is encouraging. From this experience, we believe that further improvements in this technique and the development of alternate septoplasty techniques should be cautiously pursued. We expect that ongoing development of technical alternatives will ultimately allow us to study the clinical impact of fetal LA decompression and favorably alter outcomes in this high-risk group of infants.

Acknowledgment

This work was supported in part by the Burnes Family Fund for Innovation.

References

1. Rychik J, Rome JJ, Collins MH, et al. The hypoplastic left heart syndrome with intact atrial septum: atrial morphology, pulmonary

- vascular histopathology and outcome. *J Am Coll Cardiol*. 1999;34:554–560.
2. Forbess JM, Cook N, Roth SJ, et al. Ten-year institutional experience with palliative surgery for hypoplastic left heart syndrome: risk factors related to stage I mortality. *Circulation*. 1995;92(suppl II):II-262–II-266.
3. Aiello VD, Ho SY, Anderson RH, et al. Morphologic features of the hypoplastic left heart syndrome: a reappraisal. *Pediatr Pathol*. 1990;10:931–943.
4. Atz AM, Feinstein JA, Jonas RA, et al. Preoperative management of pulmonary venous hypertension in hypoplastic left heart syndrome with restrictive atrial septal defect. *Am J Cardiol*. 1999;83:1224–1228.
5. Vlahos AP, Lock JE, McElhinney DB, et al. Hypoplastic left heart syndrome with intact or highly restrictive atrial septum: outcome after neonatal transcatheter atrial septostomy. *Circulation*. 2004;109:2326–2330.
6. Haworth SG, Reid L. Quantitative structural study of pulmonary circulation in the newborn with aortic atresia, stenosis, or coarctation. *Thorax*. 1977;32:121–128.
7. Haworth SG, Reid L. Quantitative structural study of pulmonary circulation in the newborn with pulmonary atresia. *Thorax*. 1977;32:129–133.
8. Moerman PL, Van Dijk H, Lauweryns JM, et al. Premature closure of the foramen ovale and congenital pulmonary cystic lymphangiectasis in aortic valve atresia or in severe aortic valve stenosis. *Am J Cardiol*. 1986;57:703–705.
9. Graziano JN, Heidelberger KP, Ensing GJ, et al. The influence of a restrictive atrial septal defect on pulmonary vascular morphology in patients with hypoplastic left heart syndrome. *Pediatr Cardiol*. 2002;23:146–151.
10. Antsaklis AI, Papantoniou NE, Mesogitis SA, et al. Cardiocentesis: an alternative method of fetal blood sampling for the prenatal diagnosis of hemoglobinopathies. *Obstet Gynecol*. 1992;79:630–633.
11. Kohl T, Sharland G, Allan LD, et al. World experience of percutaneous ultrasound-guided balloon valvuloplasty in human fetuses with severe aortic valve obstruction. *Am J Cardiol*. 2000;85:1230–1233.
12. Perry SB, Lang P, Keane JF, et al. Creation and maintenance of an adequate interatrial communication in left atrioventricular valve atresia or stenosis. *Am J Cardiol*. 1986;58:622–626.
13. Lenz F, Machlitt A, Hartung J, et al. Fetal pulmonary venous flow pattern is determined by left atrial pressure: report of two cases of left heart hypoplasia, one with patent and the other with closed interatrial communication. *Ultrasound Obstet Gynecol*. 2002;19:392–395.
14. Crowe DA, Allan LD. Patterns of pulmonary venous flow in the fetus with disease of the left heart. *Cardiol Young*. 2001;11:369–374.
15. Myers LB, Cohen D, Galinkin J, et al. Anaesthesia for fetal surgery. *Paediatr Anaesth*. 2002;12:569–578.
16. Gerstenfeld TS, Chang DT, Pliego AR, et al. Nonobstetrical abdominal surgery during pregnancy in Women's Hospital. *J Matern Fetal Med*. 2000;9:170–172.
17. Tworetzky W, McElhinney DB, Reddy VM, et al. Improved surgical outcome after fetal diagnosis of hypoplastic left heart syndrome. *Circulation*. 2001;103:1269–1273.
18. Jenkins PC, Flanagan MF, Jenkins KJ, et al. Survival analysis and risk factors for mortality in transplantation and staged surgery for hypoplastic left heart syndrome. *J Am Coll Cardiol*. 2000;36:1178–1185.
19. Canter CE, Moorehead S, Huddleston CB, et al. Restrictive atrial septal communication as a determinant of outcome of cardiac transplantation for hypoplastic left heart syndrome. *Circulation*. 1993;88(suppl II):II-456–II-460.