



Robin sequence: A retrospective review of 115 patients[☆]

Adele Karen Evans^{a,d,1}, Reza Rahbar^{b,d,2}, Gary F. Rogers^{c,d,3},
John B. Mulliken^{c,d,3}, Mark S. Volk^{b,d,*}

^a Massachusetts Eye and Ear Infirmary, Department of Otolaryngology,
243 Charles Street, Boston, MA 02114, USA

^b Children's Hospital Boston, Department of Otolaryngology, 300 Longwood Avenue,
Boston, MA 02115, USA

^c Children's Hospital Boston, Division of Plastic Surgery, 300 Longwood Avenue,
Boston, MA 02115, USA

^d Harvard Medical School, Boston, MA, USA

Received 8 July 2005; received in revised form 9 October 2005; accepted 18 October 2005

KEYWORDS

Pierre Robin syndrome;
Tracheotomy;
Airway obstruction;
Cleft palate

Summary

Objectives: Review a large series of patients with Robin sequence to document the incidence of (1) associated syndromic diagnoses; (2) co-morbid conditions; (3) frequency and type of operative management for airway compromise and feeding difficulties; and (4) possible differences in treatment between syndromic and non-syndromic infants.

Methods: Retrospective case-review of 115 patients with Robin sequence managed between 1962 and 2002 at two tertiary-care teaching hospitals for evaluation of demographic information, clinical findings, and treatment interventions.

Results: Fifty-four percent ($N = 63$) of patients were nonsyndromic. Syndromic patients included: Stickler syndrome (18%), velocardiofacial syndrome (7%), Treacher-Collins (5%), facial and hemifacial microsomia (3%), and other defined (3.5%) and undefined (9%) disorders. There was no statistical difference between the syndromic and nonsyndromic patients with regard to need for operative airway management

[☆] Presented at the Annual Meeting of the American Society of Pediatric Otolaryngology, Phoenix, AZ, May 2, 2004.

* Corresponding author. Tel.: +1 617 355 6460; fax: +1 617 730 0337.

E-mail addresses: adele.evans@comcast.net (A.K. Evans), reza.rahbar@childrens.harvard.edu (R. Rahbar), gary.rogers@childrens.harvard.edu (G.F. Rogers), john.mulliken@childrens.harvard.edu (J.B. Mulliken), mark.volk@childrens.harvard.edu (M.S. Volk).

¹ Tel.: +1 617 573 3654.

² Tel.: +1 617 355 6460; fax: +1 617 730 0337.

³ Tel.: +1 617 355 7686; fax: +1 617 738 1657.

(Fisher's exact test, $p = 0.264$). Forty-two percent of patients required a feeding gastrostomy tube to correct feeding difficulties. Patients with a syndromic diagnosis were more likely to be developmentally delayed.

Fifty-one (44%) patients underwent operative airway management: 61% underwent tongue–lip adhesion and 39% underwent tracheotomy. Fifteen percent of patients initially had tongue–lip adhesion subsequently required tracheotomy. While the preferred treatment for respiratory compromise differed between the two institutions, the percentage of patients requiring operative intervention was similar.

Conclusions: The pathogenesis of Robin sequence is multifactorial and syndromic in nearly half of the patients. Operative treatment of respiratory failure was required in 44% of infants; the rate was similar in both hospitals. The operative approach differed significantly between the institutions, however, based on the philosophy and training of the managing surgical specialty. Co-morbid factors such as baseline cardiopulmonary and neurologic status did not play a significant role in surgical decision making.

© 2005 Elsevier Ireland Ltd. All rights reserved.

1. Introduction

In 1923, the French stomatologist Pierre Robin described a series of infants with micro- or retrognathia, respiratory distress, and glossoptosis, with or without cleft palate [1]. This constellation of physical findings became known as Pierre Robin syndrome until 1976 when Cohen introduced the term *anomalad*, defined as “a malformation together with its subsequent derived structural changes” [2]. To reflect the fact that these anomalies occur as a developmental sequence, the name was changed to Pierre Robin sequence [3]. Linguistic purists argue that by convention the first names are not used in an eponym, and the currently accepted term is Robin sequence (RS).

As noted in Robin's original report, infants with the most severe manifestations have life-threatening respiratory compromise that impairs their ability to feed [1]. Glossoptosis, or retroposition of the tongue into the oropharynx, can obstruct the upper airway, especially while eating, resulting in poor nutrition and failure to thrive. Primary oropharyngeal dysmotility, has been noted in some patients [4–6]. Delay in achieving adequate oral intake can result in oral aversion and a dependence upon nasogastric, orogastric or gastrostomy feeding tube.

The primary management of respiratory compromise in patients with Robin sequence is controversial. Recommended protocols include prone positioning, with or without a nasopharyngeal tube [7], prolonged intubation [8–10], tongue–lip adhesion [11–14], mandibular distraction osteogenesis [6,15–17], and tracheotomy. While most authors agree that prone positioning is the treatment of choice for minor cases of Robin sequence, there is no universally accepted paradigm to determine the best treatment approach for Robin sequence patients with severe respiratory compromise.

This study analyzed a large group of patients with Robin sequence managed at two specialty hospitals in Boston: Massachusetts Eye and Ear Infirmary (MEEI) and Children's Hospital Boston (CHB). The major goals of this retrospective study were to describe the characteristics of our patient population and to identify variables that were associated with a particular therapeutic protocol.

2. Methods

Patients with a clinical diagnosis of Robin sequence were identified at each institution using multiple sources including a craniofacial database, surgical logs, and hospital-generated diagnosis codes. Records were available for MEEI over the years 1990–2002, and CHB during the period from 1962 to 2002. Patient charts were reviewed and data collected including: gender, date of birth, attending of record, diagnostic modalities, primary and associated diagnoses, treatment and age at which it was rendered, follow-up time, complications, and outcomes. A hard-copy database was assembled for each institution, and the data was entered into a HIPAA-compliant electronic database for each institution using Microsoft Excel XP[®]. The dataset was analyzed using the SAS 8.2 software program (SAS Institute Inc.; Cary, North Carolina).

3. Results

A total of 115 Robin sequence patients with complete medical records were identified—98 (85%) from CHB and 17 (15%) from MEEI. There were 57 females and 58 males. Forty-six percent of the RS patients had an identified syndrome with Stickler syndrome being the most common (Table 1).

Diagnosis	<i>n</i> (%)
Total patients	115
Non-syndromic	63 (54.8)
Syndromic	52
Stickler	21 (18.3)
Syndromic, NOS	10 (8.7)
Velo-cardio-facial	8 (7.0)
Treacher-Collins	6 (5.3)
Hemifacial microsomia	3 (2.7)
Borjesson–Forson–Lehman	1
Cornelia–DeLange	1
Freeman–Sheldon	1
Kabuki	1

3.1. Airway management

Respiratory distress was successfully addressed non-operatively in 64 patients (56%). Non-operative treatment methods evaluated were prone positioning techniques, oral airway placement, nasopharyngeal stenting and short-term intubation (<2 weeks). Treatment was considered successful (“Pass”) if no further intervention was necessary. As a primary method of airway management, prone positioning and short-term intubation had the highest success rates (52% and 43%, respectively), whereas use of the oral or nasopharyngeal airway stent was significantly less effective (only 25% and 36% success rates; Table 2). Operative intervention was undertaken for failure of non-operative treatment methods in 51 patients (44%). Surgical techniques utilized were tongue–lip adhesion (TLA; *n* = 26), tracheotomy

Treatment	<i>n</i> (%)
Positioning	31
Pass	16 (52)
Fail	15 (48)
Oral airway	4
Pass	1 (25)
Fail	3 (75)
Nasopharyngeal airway (NPA)	11
Pass	4 (36)
Fail	7 (64)
Intubation	23
Pass	10 (43)
Fail	13 (57)
Tongue–lip adhesion (TLA)	31
Pass	26 (84)
Fail	5 (16)
Tracheotomy	25

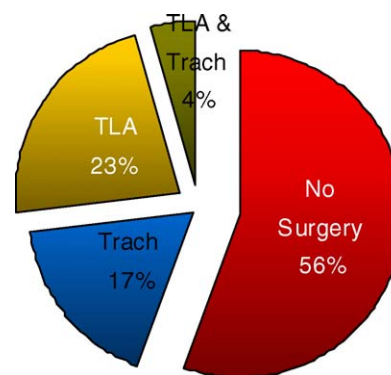


Fig. 1 Airway management techniques.

(*n* = 20), or both (*n* = 5) (Fig. 1). Five patients required tracheotomy after TLA. In three of these patients, tracheotomy was indicated to manage pulmonary toilet for aspiration associated with severe gastroesophageal reflux (GER). The other two patients were underweight (990 and 1500 g) at the time of TLA and had postoperative wound dehiscence.

Tongue–lip adhesion was performed at a mean age of 28.5 days, while tracheotomy was performed at a mean age of 85.5 days. Tracheotomy tube placement had a bimodal age distribution with one peak before 31 days and the other after 90 days. There was no statistical difference in the frequency of operative treatment between syndromic and nonsyndromic patients (Fischer exact test, *p* = 0.264).

The frequency of operative treatment was similar at both institutions (35% at CHB versus 47% at MEEI) and the difference was not statistically significant (Fisher’s exact test, *p* = 0.60). While the rate of surgical intervention was similar between institutions, the initial choice of operative procedure differed as tracheotomy was more often used at MEEI and TLA was more commonly used at CHB (Table 3). In general, there was no statistical relationship between patient diagnosis and the incidence or duration (two tailed *t*-test, *p* > 0.84) of tracheotomy (Table 4). Patients with Stickler syndrome were an exception in that they were less likely to undergo this treatment than other Robin patients (Fisher’s exact test; *p* = 0.0412). However, when confounding variables, such as

Table 3 Institution vs. preferred airway surgical intervention

	MEEI (%)	CHB (%)
Tracheotomy	83	38
TLA	16	62

Table 4 Tracheotomy patients by primary diagnostic group

Primary diagnosis	<i>n</i>	Percent of Trach Group	Percent of total (<i>n</i> = 115) ^a
Total	25		
Non-syndromic	15	60	54.8
Stickler syndrome	1	4	18.3
Presumed syndromic	3	12	8.7
Treacher-Collins syndrome	2	8	5.3
Hemifacial microsomia	2	8	2.7
Borgesson–Forson–Lehman	1	4	0.9
Freeman–Sheldon syndrome	1	4	0.9

^a From Table 1.

cardiopulmonary and neurologic differences, were controlled using logistic regression analysis, there was no significant difference in tracheotomy rates between patient with Stickler syndrome and other Robin patients ($p = 0.06$).

3.2. Feeding management

Treatment methods to address feeding difficulty included upright feeding techniques, modification of the nipple for bottle feeding, temporary use of a nasogastric or orogastric feeding tube and placement of a gastrostomy (Table 5). Feeding gastrostomy tube was required by 42% of patients ($N = 49$). Treatment was considered successful (“Pass”) if it resulted in adequate nourishment of the patient. Gastroesophageal reflux was noted in 22% ($n = 14$) of nonsyndromic and 33% ($n = 17$) of syndromic patients. These differences were not significant ($p = 0.20$).

Table 5 Feeding management

Treatment	<i>n</i> (%)
Positioning	19
Pass	6 (32)
Fail	13 (68)
Nipple	40
Pass	15 (38)
Fail	15 (63)
Temporary NGT/OGT	27
Pass	15 (57)
Fail	12 (44)
G-tube	49

3.3. Development and growth

Failure to thrive was observed in 27% ($n = 27$) of nonsyndromic patients and 37% ($n = 37$) of syndromic patients. This difference was not statistically significant ($p = 0.25$). Developmental delays were noted in a higher percentage of syndromic patients (23%, $n = 12$) than nonsyndromic patients (10%, $n = 6$), and the differences were significant ($p = 0.05$).

4. Discussion

Robin sequence describes a group of physical findings that are not only causally heterogeneous, but pathogenetically and phenotypically variable [18,19]. A sequence is defined as “a pattern of multiple anomalies derived from a single known or presumed prior anomaly or mechanical factor” [20]. Robin sequence is characterized by an underdeveloped (micrognathia) or retropositioned (retrognathia) mandible that limits space for the growing tongue. As a result, the tongue is forced to assume a posterior/elevated position in the oropharynx (glossoptosis), leading to delayed elevation/fusion of the palatal shelves (cleft palate) and respiratory distress [21,22]. The mandibular anomaly can be the result of a malformation (e.g. Treacher-Collins syndrome, hemifacial microsomia), a disruption (e.g. amniotic band), or deformation (e.g. oligohydramnios), and over 40 syndromes have been described in association with Robin sequence [20]. Accurate pathogenic diagnosis is critical to treatment, since post-natal “catch-up” growth of the mandible may depend on the underlying cause of lower jaw underdevelopment [20,19,23,24].

In the present study, 55% of the patients did not have a syndromic diagnosis. The most common syndrome associated with Robin sequence was Stickler syndrome, constituting 18% of all patients, and 40% of syndromic patients. This is similar to other reports in the literature [25–29]. Three types (I–III) of Stickler syndrome are recognized, each with a unique collagen mutation (type I, COL2A1; type II, COL11A1; type III, COL11A2). Two-thirds of Stickler syndrome cases are associated with several mutations in the COL2A1 gene.

Stickler et al. [30] reported wide phenotypic variability, which often resulted in delayed or missed diagnosis in minor cases. Certain clinical findings, however, are consistent: 95% ocular problems (retinal detachment in 60%, myopia in 90%, and blindness in 4%); 84% facial abnormalities (flat nose, small mandible, or cleft palate); 70% hearing loss; 90% degenerative joint disease and pain [30]. Tomaski et al. [25] noted that Stickler patients were

less likely to have airway and feeding issues than other syndromic Robin patients. Indeed, in our study Stickler patients were significantly less likely to have undergone tracheotomy than other Robin patients. However, the difference was not significant when potentially confounding co-morbid conditions were controlled, implying that tracheotomy may have been chosen over other treatment modalities for patients who had significant systemic illness.

The majority of infants with Robin sequence do not require operative intervention for respiratory compromise. Marques et al. [8] reported that prone positioning alone was successful in 40.3% of patients, although syndromic patients did less well than their nonsyndromic counterparts. Caouette-Laberge et al. [31], in a series of 125 Robin sequence patients, successfully used prone positioning treatment in 44.8%. Similar results with prone positioning have been reported by other authors: Schaefer et al. [14], 45%; Kirschner et al. [12], 69.2%; Cruz and coworkers [32], 55%. This method is reserved for infants with minor airway obstruction in whom treatment is short-term [32,33]. Other non-operative treatment modalities, including laryngeal mask [34,35], nasopharyngeal airway [7], and prolonged intubation [9,10,31], have been reported with variable success. In the present study, respiratory compromise was managed non-operatively in 64 patients (56%); positioning and intubation were most effective (Table 2). These techniques had treatment "failure" rates of 48% and 57%, respectively, which indicate that despite their use, another intervention was necessary to successfully support the airway. In the case of short-term intubation, the patient developed airway instability after extubation and surgical intervention with TLA or tracheotomy was necessary. Use of an oral or nasopharyngeal airway was generally unsuccessful in managing breathing difficulties and should be considered only as a temporizing measure.

Operative intervention to manage the airway is reserved for Robin sequence patients who fail, or are very likely to fail, non-operative treatment. Surgical options most commonly available and reliably studied include tongue–lip adhesion, mandibular distraction osteogenesis, and tracheotomy. Tongue–lip adhesion was first proposed by Shukowsky in 1911 to address severe respiratory compromise in Robin sequence [36]. The procedure was not widely accepted until 1940 when Douglas demonstrated improved survival in these patients by operatively tethering the tongue to the lip and alveolus [37]. Variations of Douglas' procedure have been proposed [11,38] and the indications for the procedure refined [10] in an attempt to improve the

effectiveness of tongue lip adhesion. However, these modifications have not been widely accepted, likely contributing to the variable success of tongue–lip adhesion in the literature [11–15,32,39]. Tongue–lip adhesion remains the initial procedure of choice at Children's Hospital, Boston, and the majority of these were done by the senior author (J.B.M.) using Argamaso's modification [11]. In this study, tongue–lip adhesion was successful in managing respiratory compromise in 84% of patients who underwent the procedure. We attribute this relatively high success rate to Argamaso's modification of the Routledge technique, replacing the submental button with a more secure circummandibular suture anchor [11].

Neonatal mandibular distraction osteogenesis is as a surgical technique for management of upper airway obstruction that has demonstrated success in the management of some cases of Robin Sequence [40–42]. This procedure involves the surgical placement of distraction devices to the mandible, creation of bilateral osteotomies and then distraction of the bone pieces slowly during the ensuing several weeks of healing followed by a consolidation period. One advantage is the re-proportioning of the dimensions of the mandible to ideal, which moves the base of the tongue anteriorly and hence out of the airway. Particularly for patients with certain syndromic diagnoses, such as hemifacial microsomia, this can also provide long-term dental and cosmetic benefits. Major disadvantages include the variable availability of individuals skilled in the neonatal use of the technique and the potential need for complementary intervention with intubation, TLA or tracheotomy for interim support of the unstable airway. This technique was available for older children at the participating institutions for management of mandibular asymmetry, however, it had not been regularly utilized by specialists at either institution for the neonatal management of the Robin sequence airway. This was likely due to the experience and philosophy of the Oromaxillary Facial Surgery departments in each hospital as none of the Otolaryngologic or Plastic Surgeons had training in this surgical technique.

Tracheotomy and tracheostomy are considered the most definitive methods of endotracheal airway management in patients with upper airway obstruction. Although frequently interchanged, the terms have specific meaning. Tracheotomy involves the achievement of a temporary surgical communication between the trachea and cutaneous surface in which the patency is maintained by a tracheotomy tube, whereas creation of a tracheostomy involves the direct suturing of the trachea to the cutaneous surface and requires surgical measures for reversal.

Tracheotomy is widely used in the treatment of high grade Robin sequence. Advantages are several: decreased thoracic dead-space, decreases airway resistance, permits ventilatory support, facilitates pulmonary toilet. Myer et al. [33] surveyed 23 pediatric otolaryngologic fellowship programs to clarify general treatment guidelines for patients with Robin sequence. Fifty-two percent of respondents chose tracheotomy as the treatment of choice in patients who failed observation and positioning, and 91% considered tracheotomy as a safe and reliable method of long-term airway management. By comparison, only 13% selected tongue–lip adhesion and 61% responded that tongue–lip adhesion was an inappropriate method to address long-term airway issues.

Disadvantages are likewise several: tracheotomy nursing care is specialized (and in high demand), family members require special education, nursing staff and supplies are expensive and receive variable financial support from insurance agencies. Moreover, complications related to airway management with tracheotomy are well-documented, including accidental decannulation, tube obstruction, pneumomediastinum, pneumothorax, bleeding, and tracheal stenosis [43]. Carr et al. [44] reported a 43% rate of serious complications and a 0.7% mortality rate, and most complications resulted from accidental decannulation or obstructions. Wetmore et al. [45], in a review of 450 pediatric patients managed with tracheotomy over a decade, noted a 19% rate of complications in the first postoperative week, a 58% incidence of late complications, tracheotomy-related mortality rate of 0.5%, and a nontracheotomy-related mortality of 22%. The authors also observed a trend in their center away from tracheotomy for short-term airway management, as confirmed by other authors [43]. From a large literature review, Kremer et al. [43] concluded that most fatalities of patients with tracheotomy result from their underlying medical condition and not the tracheotomy itself. In fact, several authors have reported relatively low morbidity and mortality with pediatric tracheotomy, even in neonates [46–48]. There was no mortality in our patients managed with tracheotomy.

We found that tracheotomy was the initial operative procedure at the MEEI significantly more so than at CHB (Table 3). Consistent with the study of Myer et al. [33], Otolaryngologists at MEEI and CHB rely on tracheotomy for long-term airway management, whereas the senior plastic surgeon (J.B.M.) at CHB currently favors tongue–lip adhesion. The differences in the choice initial operative procedure appear to be the result of training and specialty philosophy.

Feeding difficulties are common in Robin sequence patients, and failure to thrive rates may reach 100% [49]. Baujat et al. [50] noted feeding disorders in all 27 patients with Robin sequence in their study, including esophageal manometric abnormalities in 50%, all of which spontaneously resolved after 12 months. Based on the manometric irregularities, the authors concluded that the oroesophageal dysmotility seen in these infants probably reflects dysregulation of swallowing control from the brain stem. Heaf et al. [9] observed that failure to thrive was significantly correlated with the degree of airway obstruction. Monasterio et al. [6] found gastroesophageal reflux and dysphagia in 83% of infants with severe Robin sequence, and reported 100% resolution of these difficulties after control of the respiratory obstruction. Conversely, Kirschner et al. [12] noted that approximately 70% of patients presenting with feeding difficulty can be managed medically, and that only 30% require gastrostomy. Similarly, Cruz et al. [32] reported a gastrostomy rate of only 26%. In the present study, 73% of the patients exhibited feeding issues and 43% required a gastrostomy tube. Surprisingly, we found that even in the nonsyndromic Robin sequence population, 9.5% of the patients required prolonged gavage feeding, and 41.3% subsequently required a gastrostomy tube placement to address feeding problems.

There are several limitations of the study. First, the study was retrospective and lacks controls. While every attempt was made to identify all patients who had the diagnosis of Robin sequence, it is likely that there are patients who were not included, especially if they had minor respiratory manifestations or did not have a cleft palate. This would tend to over-represent patients who required operative treatment for their airway, since they are typically more severe. Second, multiple surgeons with different training and treatment philosophies were involved in the care of these patients. The disparity was particularly evident upon comparing operative airway management at the two hospitals. It is, therefore, impossible to retrospectively analyze the clinical decision making of each physician and deduce a generalized treatment algorithm. Third, some of the patients in the early period of the study may later have been designated as syndromic. The rapidly growing availability of genetic markers and tests over the last decade has allowed more accurate molecular diagnosis than previously available. Similarly, patients described as “nonsyndromic” today may in fact have an unknown molecular aberration that is responsible for the development of Robin sequence.

5. Conclusions

Robin sequence is pathogenetically heterogeneous; nearly half of the patients have an underlying syndromic diagnosis, the most common being Stickler syndrome. Developmental delays are more likely in syndromic patients.

Non-operative management of respiratory compromise was effective in over half of the patients; abdominal positioning and short-term intubation were more effective than oral or nasopharyngeal airway. Operative intervention was required in 44% of patients for airway compromise, and 42% of patients required feeding gastrostomy tube placement. Nonsyndromic patients were as likely to require operative treatment as syndromic patients.

Tongue–lip adhesion successfully managed respiratory compromise in the majority of patients, just as tracheotomy was effective. There was no mortality in the tracheotomy group, and the duration of tracheotomy was similar for syndromic and nonsyndromic patients. Positioning and other non-operative approaches were overall less effective than operative therapy. The rate of operative treatment was similar at both institutions, although the initial procedure differed significantly.

References

- [1] P. Robin, La chute de la base de la langue considerée comme une nouvelle cause de gêne dans la respiration naso-pharyngienne, *Bull. Acad. Med. (Paris)* 89 (1923) 37–41.
- [2] M.M. Cohen Jr., The Robin anomalad—its nonspecificity and association syndromes, *J. Oral. Surg.* 34 (7) (1976) 587–593.
- [3] J.C. Carey, R.M. Fineman, F.A. Ziter, The Robin sequence as a consequence of malformation, dysplasia, and neuromuscular syndromes, *J. Pediatr.* 101 (5) (1982) 858–864.
- [4] J.J. Baudon, F. Renault, J.M. Goutet, et al., Motor dysfunction of the upper digestive tract in Pierre Robin sequence as assessed by sucking-swallowing electro-myography and esophageal manometry, *J. Pediatr.* 140 (6) (2002) 719–723.
- [5] A.P. Bath, P.D. Bull, Management of upper airway obstruction in Pierre Robin Sequence, *J. Laryngol. Otol.* 111 (12) (1997) 1155–1157.
- [6] F.O. Monasterio, F. Molina, F. Berlanga, et al., Swallowing disorders in Pierre Robin sequence: its correction by distraction, *J. Craniofac. Surg.* 15 (6) (2004) 934–941.
- [7] I.S. Whittaker, S. Koron, D.W. Oliver, P. Jani, Effective management of the airway in Pierre Robin syndrome using a modified nasopharyngeal tube and pulse-oximetry, *Br. J. Oral. Maxillofac. Surg.* 41 (4) (2003) 272–274.
- [8] I.L. Marques, T.V. De Souza, A.F. Carneiro, et al., Clinical experience with infants with Robin sequence: a prospective study, *Cleft Palate-Craniofac. J.* 38 (2) (2001) 171–178.
- [9] D.P. Heaf, P.J. Helms, R. Dinwiddie, D.J. Matthew, Nasopharyngeal airways in Pierre Robin syndrome, *J. Pediatr.* 100 (5) (1982) 698–703.
- [10] A.E. Sher, Mechanisms of airway obstruction in Robin sequence: Implications for treatment, *Cleft Palate-Craniofac. J.* 29 (3) (1992) 224–231.
- [11] R.V. Argamaso, Glossopexy for upper airway obstruction in Robin sequence, *Cleft Palate-Craniofac. J.* 29 (3) (1992) 232–238.
- [12] R.E. Kirschner, D.W. Low, P. Randall, et al., Surgical airway management in Pierre Robin sequence: is there a role for tongue-lip adhesion? *Cleft Palate-Craniofac. J.* 40 (1) (2003) 13–18.
- [13] W. Hoffman, Outcome of tongue–lip placation in patients with severe Pierre Robin sequence, *J. Craniofac. Surg.* 5 (14) (2003) 602–608.
- [14] R.B. Schaefer, J.A. Stadler, A.K. Gosain, To distract or not to distract: an algorithm for airway management in isolated Pierre Robin sequence, *Plast. Reconstr. Surg.* 113 (4) (2004) 1113–1125.
- [15] A.D. Denny, C.A. Amm, R.B. Schaefer, Outcomes of tongue–lip adhesion for neonatal respiratory distress caused by Pierre Robin sequence, *J. Craniofac. Surg.* 15 (5) (2004) 819–823.
- [16] F.D. Burstein, J.K. Williams, Mandibular distraction osteogenesis in Pierre Robin sequence: application of a new internal single-stage resorbable device, *Plast. Reconstr. Surg.* 115 (1) (2005) 61–67.
- [17] M.A. Fritz, J.D. Sidman, Distraction osteogenesis of the mandible, *Curr. Opin. Otolaryngol. Head Neck Surg.* 12 (6) (2004) 513–518.
- [18] M.M. Cohen Jr., Robin sequence and complexes: causal heterogeneity and pathogenetic/phenotypic variability, *Am. J. Med. Genet.* 84 (1999) 311–315.
- [19] S. Pruzanski, Not all dwarfed mandibles are alike, *Birth Defects* 5 (1969) 120–129.
- [20] J.W. Spranger, K. Benirschke, J.G. Hall, et al., Errors in morphogenesis: concepts and terms, *J. Pediatr.* 100 (1982) 160–165.
- [21] K.L. Moore, T.V.N. Persaud, *The Developing Human*, 7th ed., Saunders, Philadelphia, 2003, pp. 202–240.
- [22] G.H. Sperber, Palatogenesis: closure of the secondary palate, in: D.F. Wyszinski (Ed.), *Cleft Lip and Palate: From Origin to Treatment*, Oxford University Press, Oxford, 2002, pp. 14–24.
- [23] M. Hotz, W. Gnoinski, Clefts of the secondary palate associated with the 'Pierre Robin Syndrome', *Swed. Dent. J.* 6 (Suppl. 15) (1982) 89–98.
- [24] A.A. Figueroa, T.J. Glupker, M.G. Fitz, E.A. BeGole, Mandible, tongue and airway in Pierre Robin sequence: a longitudinal cephalometric study, *Cleft Palate J.* 28 (1991) 425–434.
- [25] S.M. Tomaski, G.H. Zalzal, H.M. Saal, Airway obstruction in the Pierre Robin sequence, *Laryngoscope* 105 (2) (1995) 111–114.
- [26] R.J. Shprintzen, Pierre Robin, micrognathia and airway obstruction: the dependency of treatment on accurate diagnosis, *Int. Anesthesiol. Clinics* 26 (1) (1988) 64–71.
- [27] R.L. Schreiner, W.H. McAlister, R.E. Marshall, W.T. Sheares, Stickler syndrome in a pedigree of Robin syndrome, *Am. J. Dis. Child.* 126 (1973) 86–90.
- [28] M. Holder-Espinasse, V. Abadie, V. Cormier-Daire, et al., Pierre Robin sequence: a series of 117 consecutive cases, *J. Pediatr.* 139 (4) (2001) 588–590.
- [29] A. Printzlau, M. Anderson, Pierre Robin sequence in Denmark: a retrospective population-based epidemiologic study, *Cleft Palate-Craniofac. J.* 41 (1) (2004) 47–52.
- [30] G.B. Stickler, W. Hughes, P. Houchin, Clinical features of hereditary progressive arthroophthalmopathy (Stickler syndrome): a survey, *Genet. Med.* 3 (2001) 192–196.
- [31] L. Caouette-Laberge, B. Bayet, Y. Larocque, The Pierre Robin sequence: review of 125 cases and evolution of treatment modalities, *Plast. Reconstr. Surg.* 93 (1994) 934–941.

- [32] D.P. Heaf, M.J. Cruz, J.E. Kerschner, D.J. Beste, S.F. Conley, Pierre Robin sequences: secondary respiratory difficulties and intrinsic feeding abnormalities, *Laryngoscope* 109 (10) (1999) 1632–1636.
- [33] C.M. Myer III, J.M. Reed, R.T. Cotton, J.P. Willging, S.R. Shott, Airway management in Pierre Robin sequence, *Otolaryngol. Head Neck Surg.* 118 (5) (1998) 630–635.
- [34] C.T. Yao, J.N. Wang, Y.T. Tai, et al., Successful management of a neonate with Pierre-Robin syndrome and severe upper airway obstruction by long-term placement of a laryngeal mask airway, *Resuscitation* 61 (1) (2004) 97–99.
- [35] D. Gandini, J. Brimacombe, Laryngeal mask airway for ventilatory support over a 4-day period in a neonate with Pierre Robin sequence, *Paediatr. Anaesth.* 13 (2) (2003) 181–182.
- [36] W.P. Shukowsky, Zur ratiologie des stridor inspiratorius congenitus, *Jahrb. Kinderheilk.* 73 (1911) 459.
- [37] B. Douglas, The treatment of micrognathia associated with obstruction by a plastic procedure, *Plast. Reconstr. Surg.* 1 (1946) 300–308.
- [38] R.T. Routledge, The Pierre Robin syndrome: a surgical emergency in the neonatal period, *Br. J. Plast. Surg.* 13 (1960) 204–218.
- [39] F. Huang, L.J. Lo, Y.R. Chen, et al., Tongue-lip adhesion in the management of Pierre Robin Sequence with airway obstruction: technique and outcome, *Chang Gung Med. J.* 28 (2) (2005) 90–96.
- [40] A.D. Denny, R. Talisman, P.R. Hanson, R.F. Recinos, Mandibular distraction osteogenesis in very young patients to correct airway obstruction, *Plast. Reconstr. Surg.* 108 (2) (2001) 302–311.
- [41] A. Denny, B. Kalantarian, Mandibular distraction in neonates: a strategy to avoid tracheostomy, *Plast. Reconstr. Surg.* 109 (3) (2002) 896–904.
- [42] F.O. Monasterio, M. Drucker, F. Molina, A. Ysunza, Distraction osteogenesis in Pierre Robin Sequence and related respiratory problems in children, *J. Craniofac. Surg.* 13 (1) (2002) 79–83.
- [43] B. Kremer, A.I. Botos-Kremer, H.E. Eckel, G. Schlondorff, Indications, complications, and surgical techniques for pediatric tracheostomies—an update, *J. Pediatr. Surg.* 37 (11) (2002) 1556–1562.
- [44] M.M. Carr, C.P. Poje, L. Kingston, et al., Complications in pediatric tracheostomies, *Laryngoscope* 111 (11) (2001) 1925–1928.
- [45] R.F. Wetmore, R.R. Marsh, M.E. Thompson, L.W. Tom, Pediatric tracheostomy: a changing procedure? *Ann. Otol. Rhinol. Laryngol.* 108 (7 Pt. 1) (1999) 695–699.
- [46] A. Alladi, S. Rao, K. Das, et al., Pediatric tracheostomy: a 13-year experience, *Pediatr. Surg. Int.* 20 (9) (2004) 695–698.
- [47] B.W. Duncan, L.J. Howell, A.A. de Lorimer, et al., Tracheostomy in children with emphasis on home care, *J. Pediatr. Surg.* 27 (4) (1992) 432–435.
- [48] K.D. Pereira, A.R. MacGregor, C.M. McDuffie, R.B. Mitchell, Tracheostomy in preterm infants: current trends, *Arch. Otolaryngol. Head Neck Surg.* 129 (12) (2003) 1268–1271.
- [49] A.N. Pandya, J.G. Boorman, Failure to thrive in babies with cleft lip and palate, *Br. J. Plast. Surg.* 54 (6) (2001) 471–475.
- [50] G. Baujat, C. Faure, A. Zaouche, et al., Oropharyngeal motor disorders in Pierre Robin syndrome, *J. Pediatr. Gastroenterol. Nutr.* 32 (3) (2001) 297–302.

Available online at www.sciencedirect.com

