

# Robotic Surgery in the Pediatric Airway

## Application and Safety

Reza Rahbar, DMD, MD; Lynne R. Ferrari, MD; Joseph G. Borer, MD; Craig A. Peters, MD

**Objective:** To assess the application and safety of transoral robotic surgery in the pediatric airway.

**Design:** An institutional review board–approved study. Experimental laryngeal surgery was performed on 4 pediatric cadaver larynxes as controls. Application of robotic equipment for laryngeal surgery was attempted on 5 patients.

**Setting:** Tertiary care pediatric medical center.

**Patients:** Five patients with laryngeal cleft and 4 pediatric cadaver larynxes.

**Interventions:** (1) The da Vinci Surgical Robot (Intuitive Surgical Inc, Sunnyvale, Calif) was used on 4 cadaver larynxes and assessed for the dexterity, precision, and depth perception that it allowed the surgeon during laryngeal surgery. Procedures were documented with still and video photography. (2) The da Vinci Surgical Robot was used through a transoral approach to attempt repair of a laryngeal cleft in 5 pediatric patients who were under spontaneously breathing general anesthesia.

**Results:** (1) Use of the surgical robot on cadaver larynxes provided great dexterity and precision, delicate tissue handling, good 3-dimensional depth perception, and relatively easy endolaryngeal suturing. (2) The surgical robot could not be used for repair of laryngeal cleft on 3 patients owing to limited transoral access. However, 1 patient with a type 1 laryngeal cleft and 1 patient with a type 2 laryngeal cleft underwent transoral robotic repair with great success.

**Conclusions:** Surgical robots provide the ability to manipulate instruments at their distal end with great precision, increased freedom of movement, and excellent 3-dimensional depth perception. The size of the equipment can be a limiting factor with regard to the application and success of the transoral approach to airway surgery. We believe that further advances in device technology and a new generation of robotic equipment will facilitate the incorporation of surgical robotics in the advancement of minimally invasive endoscopic airway surgery.

*Arch Otolaryngol Head Neck Surg.* 2007;133:46-50

THE DESIRE TO MOVE TOWARD minimally invasive surgery and procedures with less morbidity has been the driving force behind the development and application of robotic surgery. Over the past decades, robotic surgical systems have been used in laparoscopic, thoracoscopic, cardiac, and urologic surgical procedures.<sup>1-4</sup> Despite these recent advances, the introduction of surgical robotics to the practice of otolaryngology is still limited by anatomic constraints, especially in pediatric patients. The objective of this study was to evaluate the application, efficacy, and safety of the da Vinci Surgical Robot (Intuitive Surgical Inc, Sunnyvale, Calif) in the pediatric airway.

### METHODS

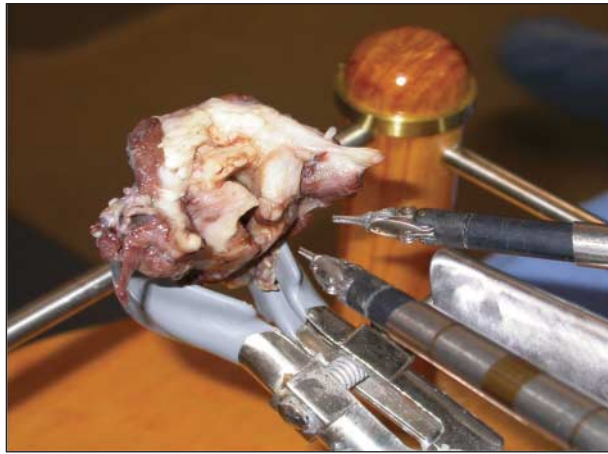
After review and approval by the Children's Hospital Boston Department of Clinical Investigation, we obtained 4 pediatric cadaver larynxes for study purposes in the laboratory setting. The da Vinci Surgical Robot was assessed for the dexterity, precision, and depth perception it pro-

vided the surgeon during laryngeal surgery. Different combinations of laryngoscopes, endoscopes, and microinstruments were used to identify the best setup for robot-assisted airway operation. Both 8-mm, 2-dimensional and 12-mm, 3-dimensional endoscopes of 0° and 30° were used to assess the impact on exposure. Also, 5-mm and 8-mm microinstruments were used to determine the degree of range of motion.

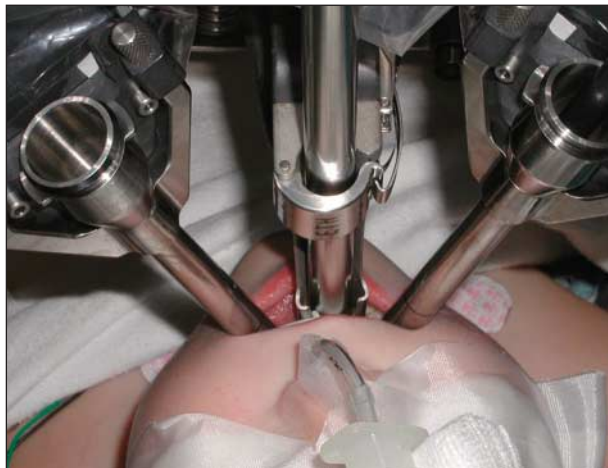
### See Invited Commentary at end of article

The cadaveric larynxes were fixed to a laryngeal holder (**Figure 1**). The da Vinci system was set up in a fashion similar to that used in the operating room. Procedures were documented with still and video photography. Application of the da Vinci Surgical Robot was attempted in 5 patients (2 boys and 3 girls) undergoing endoscopic repair of laryngeal cleft between 2003 and 2006. The mean patient age was 5 years (age range, 1-14 years). Three patients had a type 1 laryngeal cleft, and 2 patients had a type 2 cleft. All 5 patients had a history of multiple pneumonias, documented aspiration on swallow study, and failed conservative monitoring.

**Author Affiliations:** Departments of Otolaryngology and Communication Disorders (Dr Rahbar), Anesthesia (Dr Ferrari), and Urology (Dr Borer), Children's Hospital Boston, Harvard Medical School, and Department of Otolaryngology, Harvard Medical School (Dr Rahbar), Boston, Mass; and Department of Urology, University of Virginia, Charlottesville (Dr Peters).



**Figure 1.** Laryngeal holder (designed by Seth H. Daily, MD).

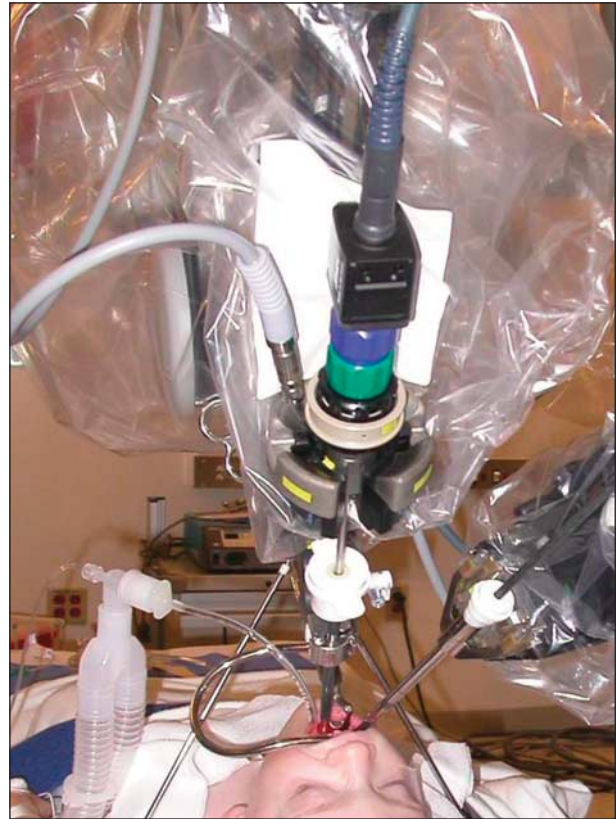

**Figure 2.** Robotic equipment with suspension using a Lindholm laryngoscope.

An essential component of this procedure is the ability of the surgeon to have an unobstructed view of the larynx. Conventional anesthetic airway management does not provide ideal surgical conditions because the presence of an endotracheal tube impedes the view and restricts access to the surgical site. For this reason, we used a technique of spontaneous ventilation without an artificial airway. Anesthetic induction was achieved by either inhalation of sevoflurane in oxygen and nitrous oxide or intravenous administration of propofol. Spontaneous ventilation was maintained, and an infusion of propofol and remifentanyl was used to maintain unconsciousness. The vocal cords and surgical site were sprayed with 4% lidocaine to provide the analgesic component of the anesthetic. To use this technique safely, the anesthesiologist must have full view of the vocal cords on a video monitor at all times and be listening to the breath sounds with a precordial stethoscope in addition to monitoring the physiologic parameters.

## RESULTS

Robotic surgery on cadaver larynxes allowed the surgeon great dexterity and precision, delicate tissue handling, good 3-dimensional depth perception, and relatively easy endolaryngeal suturing. In the laboratory setting, we did not see any major difference between 0° and 30° with regard to access. Trial of the 8-mm, 2-dimensional endoscope and the

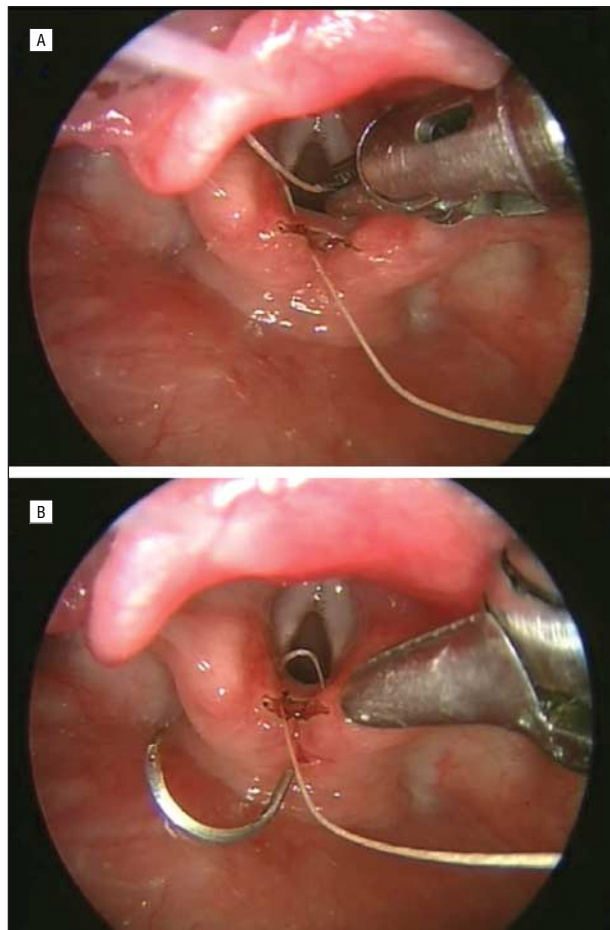


**Figure 3.** Robotic equipment with suspension using a Crowe-Davis mouth gag.

12-mm, 3-dimensional endoscope provided similar instrument excursion. However, with the 8-mm, 2-dimensional endoscope, depth perception was lost. Trial of suturing within the endolarynx was successful using 5-0 and 6-0 Vicryl sutures (Ethicon Inc, Somerville, NJ).

Robotic surgery for repair of laryngeal cleft could not be performed in 3 patients owing to limited transoral access. One patient with a type 1 laryngeal cleft and 1 patient with type 2 laryngeal cleft underwent transoral robotic repair with good success. Initial setup of the surgical suite for robotic equipment was achieved in 40 minutes. All procedures were performed using suspension microlaryngoscopy under general anesthesia with spontaneous breathing. The carbon dioxide laser was set at 3 W and 0.3-second intermittent mode to denude the mucosal margin of the cleft. In the initial attempts, suspension was achieved using a Lindholm laryngoscope under spontaneous general anesthesia. The endoscope was passed through the lumen of the laryngoscope, and both robotic arms were passed through the oral cavity along the sides of the laryngoscope. The exposure was adequate for the supraglottis and glottis with both 0° and 30° endoscopes. Owing to the narrow confines of the oropharynx, we were unable to maneuver the instruments and had a very limited freedom of motion with both the 5-mm and 8-mm instruments.

Although suspension with the Lindholm laryngoscope provided the best direct access, we were not able to maneuver the instruments in any patients owing to limited space (**Figure 2**). Suspension with a Crowe-Davis mouth gag provided adequate exposure and more space to maneuver the robotic arms (**Figure 3**). The entire hypopharynx and su-



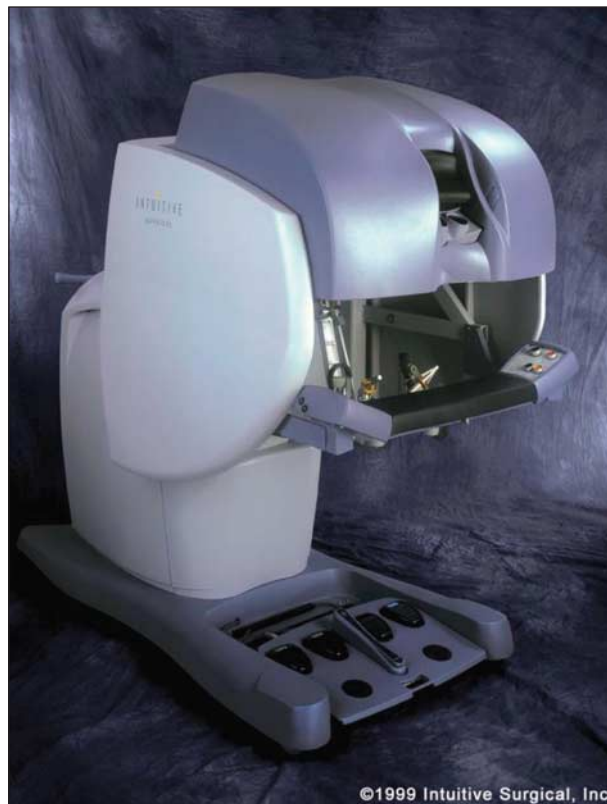**Figure 4.** Placement of suture using robotic equipment from beginning (A) to end (B) of placement.

praglottis could be visualized using a 0° endoscope; however, the 30° endoscope was far superior for exposure of the glottis. We achieved adequate exposure to place sutures for closure of laryngeal cleft (**Figure 4**) in 2 patients. The ability to move the endoscope further or closer from the area being sutured allowed for excellent magnification on close-up view. The application of robotic equipment prolonged the procedure by an average of 40 minutes compared with the routine endoscopic approach.

#### COMMENT

In the 1980s, robotic technology advanced when researchers at NASA (the National Aeronautics and Space Administration) proposed the idea of a surgeon-controlled robotic handpiece as an extension of NASA-developed virtual reality technology.<sup>5</sup> The US Department of Defense became interested in the potential application of this technology to the battlefield that would allow a surgeon to operate on a wounded soldier from a remote location. This technology has shown its greatest growth in commercial systems, with the emphasis on advancement of minimally invasive procedures.

Using robotic technology first developed by Computer Motion Inc (Goleta, Calif), miniaturized robots, coupled with improvement of 3-dimensional optic tech-



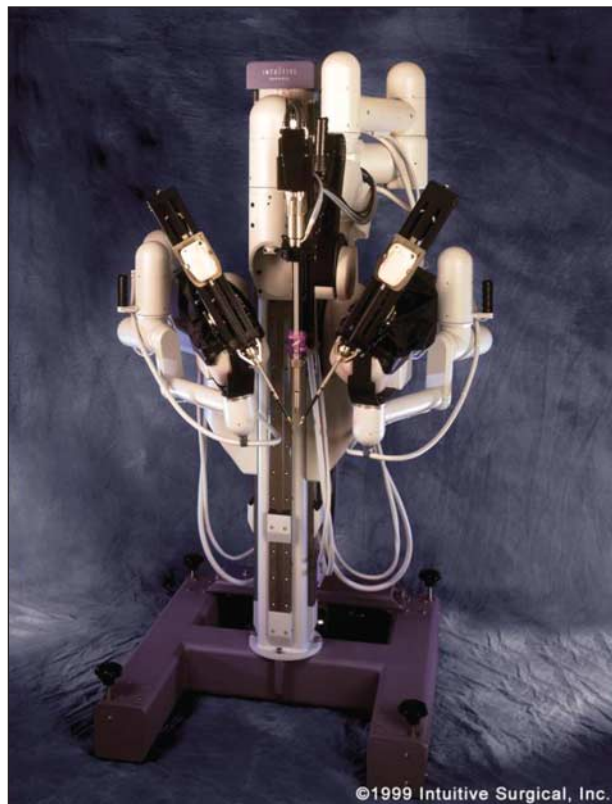
**Figure 5.** Surgeon's console component of the da Vinci Surgical Robot (Intuitive Surgical Inc, Sunnyvale, Calif; photograph used with permission).

nology, have prepared the way for applications of surgical robotic technology. The use of robot-assisted equipment can provide surgeons with improved dexterity and precision coupled with advanced imaging techniques with 3-dimensional depth perception. It can also provide a means to overcome surgical limitations such as site obstruction and a limited operative field.

Surgical robots may be active, semiactive, or passive. An active robot is programmed to perform an entire procedure without any input from the surgeon. A semiactive robot requires input from the surgeon to carry out powered directed activity. A passive robot is completely controlled by the surgeon. Telerobotic surgery is based on technology that allows a surgeon to operate from a remote console with a virtual 3-dimensional vision system.<sup>6</sup> This technology received extensive publicity when a laparoscopic cholecystectomy was performed on a patient in Strasbourg, France, by a surgeon seated 3800 miles away in New York, NY.<sup>7</sup>

Robotic equipment offers several advantages. First, surgical robots provide 3-dimensional endoscopic vision, which gives the surgeon true depth perception. Second, surgical robots provide increased freedom of movement of microendoscopic instruments, including simulated flexion, extension, pronation, and supination of instruments at their distal tip.<sup>8,9</sup> Third, robotic equipment allows for scaling of movement, translating large movements of the hands into small movements of the instruments, thus filtering tremor.<sup>9</sup>

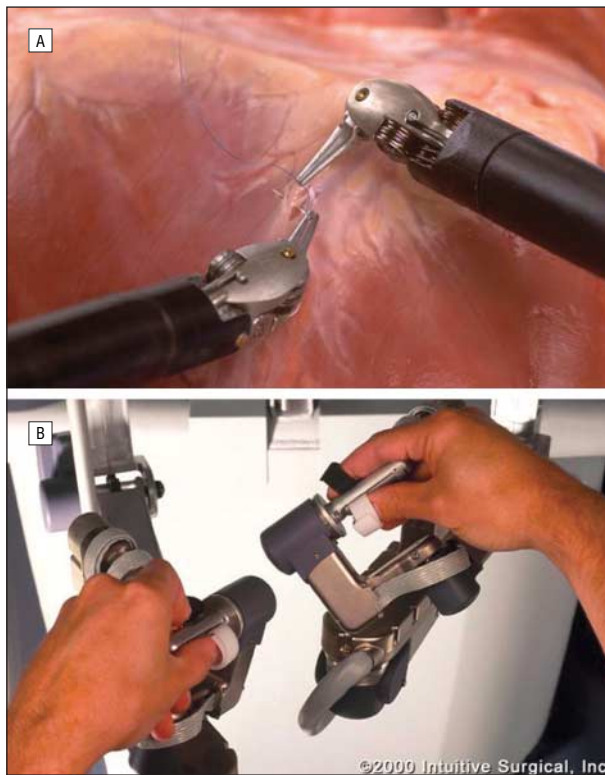
The da Vinci system is the first surgical robot to be approved by the US Food and Drug Administration for general laparoscopic surgery. It is composed of 3 components: a surgeon's console (**Figure 5**), a surgical cart



**Figure 6.** Surgical cart component of the da Vinci Surgical Robot (Intuitive Surgical Inc, Sunnyvale, Calif; photograph used with permission).

(**Figure 6**), and a vision cart (**Figure 7**). The surgeon's console displays a superb 3-dimensional view by having a separate monitor for the left and right eye views. At the console, the surgeon controls the instrument arms and camera by maneuvering the master robotic manipulators. The surgical cart is equipped with a robotic manipulator and 3 mounted arms: 1 arm holds the camera, and the other 2 hold either 5-mm or 8-mm instruments. The vision cart is equipped with 2 three-chip cameras mounted within 1 integrated 12-mm stereoscopic endoscope.<sup>10,11</sup> The arms of the EndoWrist instruments (Intuitive Surgical Inc) have a total of 7 degrees of freedom, including pitch, yaw, roll, 2 degrees in the wrist, and 2 for tool actuation.<sup>12-14</sup>

Use of robotic-assisted surgery has been reported for cholecystectomy, Nissen fundoplication, prostatectomy, splenectomy, and closure of patent ductus arteriosus in the pediatric population.<sup>15</sup> The application of robotic-assisted excision of a vallecular cyst has also been reported in an adult patient.<sup>16</sup> The robotic equipment is designed to provide 3 widely spaced ports of entry into the thorax or abdomen. The primary hurdle to the application of the da Vinci Surgical Robot is the means of introducing large robotic arms into the single funnel created by the mouth. Also, most laryngoscopes are closed tubes, which further limits endoscope movements. We encountered several challenges in the use of robotic equipment for airway surgery: (1) obtaining a safe, adequate means to administer airway anesthesia; (2) obtaining proper exposure of the larynx to perform the surgery; (3) the need to introduce the robotic arms into a single port



**Figure 7.** Vision cart component of the da Vinci Surgical Robot (Intuitive Surgical Inc, Sunnyvale, Calif; photographs used with permission). Surgeon placing a suture under a 3-dimensional view of the surgical site (A), using the Endo Wrist instrument (Intuitive Surgical Inc) (B).

of entry (oral cavity or pharynx) and overcome limitation of movement; and (4) the lack of availability of suction instruments.

However, robot-assisted surgery has certain advantages over conventional endoscopic surgery: (1) improved optics, with 3-dimensional visualization; (2) tremor filtration; and (3) increased freedom of instrument movement, which allows for delicate handling of tissues and increased surgical precision. Based on our work, it seems that the best exposure and range of motion could be accomplished with suspension using the Crowe-Davis mouth gag combined with the 3-dimensional, 30° endoscope and the 5-mm instruments for work at the glottic level. We tried a flexible suction catheter in the surgical field, which could be used by the robotically controlled instruments. The development of instruments with integrated suction could also alleviate this problem. We also found endolaryngeal suturing to be relatively easy with robotic equipment, once the adequate exposure was achieved. Also, it seems that there is potential for much more gentle handling of tissues owing to filtration of tremor. We believe that the development of smaller instruments and further advances and modifications in device technology will facilitate the incorporation of robotic equipment into otolaryngology.

**Submitted for Publication:** July 21, 2006; accepted August 17, 2006.

**Correspondence:** Reza Rahbar, DMD, MD, Department of Otolaryngology, Children's Hospital Boston, Harvard

Medical School, 300 Longwood Ave, Boston, MA 02115 (reza.rahbar@childrens.harvard.edu).

**Author Contributions:** Dr Rahbar had full access to all the data in the study and takes responsibility for the integrity of the data and the accuracy of the data analysis. **Study concept and design:** Rahbar. **Acquisition of data:** Rahbar, Ferrari, Borer, and Peters. **Analysis and interpretation of data:** Ferrari and Peters. **Drafting of the manuscript:** Rahbar. **Critical revision of the manuscript for important intellectual content:** Rahbar, Ferrari, Borer, and Peters. **Administrative, technical, and material support:** Rahbar, Ferrari, Borer, and Peters. **Study supervision:** Rahbar.

**Financial Disclosure:** None reported.

**Previous Presentation:** This article was presented at American Society of Pediatric Otolaryngology meeting; May 2006; Chicago, Ill.

## REFERENCES

1. Boehm DH, Arnold MV, Dettler C, Reichenspurner HC. Incorporating robotics into an open-heart program. *Surg Clin North Am.* 2003;83:1369-1380.
2. Binder J, Brautigam R, Jonas D, Bentas W. Robotic surgery in urology: fact or fantasy? *BJU Int.* 2004;94:1183-1187.
3. Jacobsen G, Berger R, Horgan S. The role of robotic surgery in morbid obesity. *J Laparoendosc Adv Surg Tech A.* 2003;13:279-283.
4. Advincula AP, Falcone T. Laparoscopic robotic gynecologic surgery. *Obstet Gynecol Clin North Am.* 2004;31:599-609.
5. Satava RM. Surgical robotics: the early chronicles. *Surg Laparosc Endosc Percutan Tech.* 2002;12:6-16.
6. Ballantyne GH. Robotic surgery, telerobotic surgery, telepresence and telementoring. *Surg Endosc.* 2002;16:1389-1402.
7. Marescaux J, Leroy J, Gagner M, et al. Transatlantic robot-assisted telesurgery. *Nature.* 2001;413:379-380.
8. Hockstein NG, Nolan PJ, O'Malley BW, Woo YJ. Robotic microlaryngeal surgery: a technical feasibility study using the da Vinci surgical robot and an airway mannequin. *Laryngoscope.* 2005;115:780-785.
9. Haus BM, Kambbam N, Le D, et al. Surgical robotic applications in otolaryngology. *Laryngoscope.* 2003;113:1139-1144.
10. Marescaux J, Leroy J, Rubino F, et al. Transcontinental robot-assisted remote tele-surgery: feasibility and potential applications. *Ann Surg.* 2002;235:487-492.
11. Mack MJ. Minimally invasive and robotic surgery. *JAMA.* 2001;285:568-572.
12. Sung GT, Gill IS. Robotic laparoscopic surgery: a comparison of the da Vinci and Zeus systems. *Urology.* 2001;58:893-898.
13. Buckingham RA, Buckingham RO. Robots in operating theatres. *BMJ.* 1995;311:1479-1482.
14. McLeod IK, Mair EA, Melder PC. Potential applications of the da Vinci minimally invasive surgical robotic system in otolaryngology. *Ear Nose Throat J.* 2005;84:483-487.
15. Lorincz A, Langenburg S, Klein MD. Robotics and the pediatric surgeon. *Curr Opin Pediatr.* 2003;15:262-266.
16. McLeod IK, Melder PC. Da Vinci robot-assisted excision of a vallecular cyst: a case report. *Ear Nose Throat J.* 2005;84:170-172.

## Invited Commentary

**R**obotic surgery has found its way into numerous specialties and in some cases has become the procedure of choice. Robotic surgical procedures of the prostate, heart, and abdominal organs are examples of the clinical application of this technology. Applications in otolaryngology—head and neck surgery have been slow to develop because (1) access has always been readily gained through body orifices and (2) the skin in the head and neck region heals superbly well. However, the growing potential for otolaryngologists to use surgical robots to perform delicate operations with fine motor control and minimal tremor is creating a greater demand for their use, particularly for procedures involving small structures.

Rahbar and associates report an application in the pediatric airway after initial assessment in cadaveric specimens. Endoscopic repair of laryngeal clefts has been reported by Benjamin and Inglis<sup>1</sup> for types 1 and 2 clefts.<sup>2</sup> Recently, Sandu and Monnier<sup>3</sup> reported a small series of endoscopically managed extended laryngotracheal clefts (type 3 or greater). In the present study, Rahbar and associates attempted robot-assisted endoscopic repair of laryngeal clefts in 5 patients, 3 with type 1 and 2 with type 2 clefts. This approach needed to be abandoned in 3 patients owing to a number of obstacles, the most significant being inadequate transoral access for the robotic instruments.

The da Vinci Surgical Robot (Intuitive Surgical Inc, Sunnyvale, Calif) is presently the only device of its kind approved by the US Food and Drug Administration, but robots will soon be made smaller and technically more sophisticated. They will be integrated into systems that include preoperative imaging devices, simulators on which the procedure can be rehearsed, and navigation devices to help guide the robots during the procedure. This integrated network will also include telecommunication components so that it can be used over great distances. The surgeons guiding the robots will be true experts, wherever they are in the world, without the need to be in proximity to the patient. Because of the obvious military applications of this feature for wounded personnel, the US Department of Defense has supported research in this area. The potential to improve patient safety is apparent and has gained the interest of surgical specialty societies and boards worldwide.

The level of sophistication and range of applications of robotic surgery will soon be expanded. Rahbar et al describe a novel application to pediatric laryngology, and they should be commended for their approach. We look forward to more such communications and the excitement generated by such advances in the clinical application of robotic technology.

Marvin P. Fried, MD  
Sanjay R. Parikh, MD

1. Benjamin B, Inglis A. Minor congenital laryngeal clefts: diagnosis and classification. *Ann Otol Rhinol Laryngol.* 1989;98:417-420.
2. Kubba H, Gibson D, Bailey M, Hartley B. Techniques and outcomes of laryngeal cleft repair: an update to the Great Ormond Street Hospital Series. *Ann Otol Rhinol Laryngol.* 2005;114:309-313.
3. Sandu K, Monnier P. Endoscopic laryngotracheal cleft repair without tracheotomy or intubation. *Laryngoscope.* 2006;116:630-634.