

Balloon Dilation of Severe Aortic Stenosis in the Fetus Potential for Prevention of Hypoplastic Left Heart Syndrome Candidate Selection, Technique, and Results of Successful Intervention

Wayne Tworetzky, MD; Louise Wilkins-Haug, MD, PhD; Russell W. Jennings, MD; Mary E. van der Velde, MD; Audrey C. Marshall, MD; Gerald R. Marx, MD; Steven D. Colan, MD; Carol B. Benson, MD; James E. Lock, MD; Stanton B. Perry, MD

Background—Preventing the progression of fetal aortic stenosis (AS) to hypoplastic left heart syndrome (HLHS) requires identification of fetuses with salvageable left hearts who would progress to HLHS if left untreated, a successful in utero valvotomy, and demonstration that a successful valvotomy promotes left heart growth in utero. Fetuses meeting the first criterion are undefined, and previous reports of fetal AS dilation have not evaluated the impact of intervention on in utero growth of left heart structures.

Methods and Results—We offered fetal AS dilation to 24 mothers whose fetuses had AS. At least 3 echocardiographers assigned a high probability that all 24 fetuses would progress to HLHS if left untreated. Twenty (21 to 29 weeks' gestation) underwent attempted AS dilation, with technical success in 14. Ideal fetal positioning for cannula puncture site and course of the needle (with or without laparotomy) proved to be necessary for procedural success. Serial fetal echocardiograms after intervention demonstrated growth arrest of the left heart structures in unsuccessful cases and in those who declined the procedure, while ongoing left heart growth was seen in successful cases. Resumed left heart growth led to a 2-ventricle circulation at birth in 3 babies.

Conclusions—Fetal echocardiography can identify midgestation fetuses with AS who are at high risk for developing HLHS. Timely and successful aortic valve dilation requires ideal fetal and cannula positioning, prevents left heart growth arrest, and may result in normal ventricular anatomy and function at birth. (*Circulation*. 2004;110:2125-2131.)

Key Words: aortic valve stenosis ■ balloon dilatation ■ fetus ■ hypoplastic left heart syndrome

Anatomic cardiac obstructions that cause ventricular dysfunction can divert fetal blood flow in utero and result in cardiac chamber hypoplasia.¹⁻⁵ Thus, severe aortic stenosis (AS) in midgestation may lead to myocardial damage, ultimately resulting in hypoplastic left heart syndrome (HLHS). HLHS, lethal when untreated, occurs when the left ventricle (LV) cannot support the systemic circulation. In some midgestation fetuses with severe AS, the LV size is normal or even enlarged, but as gestation progresses, left heart growth is retarded,⁶⁻⁸ leading to HLHS. Even after ≥ 2 successful palliative surgeries, the child with HLHS is left with single-ventricle circulation. Thus, expectant parents confront the difficult choice between pregnancy termination and delivering a baby with the unalterable prospect of lifelong cardiac disability. Theoretically, early relief of fetal AS might preserve left heart function and flow (and even growth) in utero and perhaps prevent HLHS altogether. To that end, in utero

aortic valvuloplasty has been attempted, as reported, in 12 third-trimester fetuses.⁹⁻¹¹ These previously reported procedures have had limited technical success, high mortality, and no documentation of improved growth of the left heart structures.

Prevention of HLHS by relieving AS in utero requires answers to 3 questions: Can fetal echocardiography identify fetuses with potentially salvageable left hearts who would likely go on to develop HLHS; can aortic valvuloplasty be performed successfully and safely in such fetuses; and does a successful in utero aortic valvuloplasty restore adequate flow to permit left heart growth in utero?

Improvements in fetal imaging and diagnosis, maternal and fetal anesthesia and surgical manipulation,¹² and angioplasty tools and techniques prompted us to begin an innovative therapy program at Children's Hospital Boston and the Brigham and Women's Hospital in early 2000. This program

Received December 30, 2003; revision received May 28, 2004; accepted June 4, 2004.

From the Departments of Cardiology (Children's Hospital) and Pediatrics (Harvard Medical School) (W.T., M.E.v.d.V., A.C.M., G.R.M., S.D.C., J.E.L., S.B.P.); Department of Surgery, Children's Hospital and Harvard Medical School (R.W.J.); Department of Obstetrics and Gynecology, Brigham and Women's Hospital and Harvard Medical School (L.W.-H.); and Department of Radiology, Brigham and Women's Hospital and Harvard Medical School (C.B.B.), Boston, Mass. Dr Perry currently is at Packard Children's Hospital, Stanford, Calif.

Correspondence to Wayne Tworetzky, MD, Department of Cardiology Children's Hospital Boston, 300 Longwood Ave, Boston MA 02115. E-mail wayne.tworetzky@cardio.chboston.org

© 2004 American Heart Association, Inc.

Circulation is available at <http://www.circulationaha.org>

DOI: 10.1161/01.CIR.0000144357.29279.54

Clinical Summary of Fetuses in a Pilot Study That Were Considered Candidates for In Utero Aortic Valvuloplasty

Patient	GA at Diagnosis, wk	GA at Intervention, wk	Aortic Valve Lesion	LV Dysfunction	EB	Atrial Septum (Left to Right)	Aortic Arch Flow	MR	LV Length z Score at Diagnosis	LV Length z Score at Intervention	Balloon Inflation Diameter, mm
1	22	29	S	+++	+	+	R	+	0.65	-3.9	NA
2*	20	23	S	+++	+	++	R	+	4.7	2.9	2.96
3	19	21	A	+++	+	+	R	+	1.3	-0.65	NA
4	26	29	S	+++	++	+	R	+	-0.45	-1.8	NA
5	20	22	A	+++	+	+	R	++	1.3	-0.5	2.75
6	25	26	S	+++	+	+++	R	+++	8.8	7.3	3.35
7	23	24	S	+++	++	+	R	++	2.2	0.05	2.62
8	24	25	S	+++	+	+	R	0	-1.0	-1.2	2.83
9	23	24	S	+++	++	+	R	++	-0.05	-3.5	NA
10	22	23	S	+++	+	++	R	+	2.6	1.8	2.62
11	18	20	S	+++	++	+	R	+	3.1	-2.0	NA
12	23	23	S	+++	+	+	R	++	4.5	3.7	3.0
13	22	24	S	+++	+	+	R	++	2.56	1.83	NA
14*	22	23	S	+++	+	+	R	0	2.34	1.59	3.2
15	23	24	S	+++	++	+	R	+	4.8	4	2.7
16*	24	25	S	+++	+	+	R	0	0.4	-0.2	3.3
17	22	23	S	+++	++	++	R	0	4.75	3.9	3.3
18	21	22	S	+++	+	+	R	++	1.4	0.65	2.7
19	23	24	S	+++	++	+	R	+	2.9	1.5	3.6
20	23	23	S	+++	++	+	R	++	4.4	4.4	3.1
21	19	N/a	S	+++	+	++	R	+	-1.4	NA	NA
22	28	N/a	S	+++	++	+++	R	0	2.2	NA	NA
23	23	N/a	S	+++	++	+	R	++	-1.5	NA	NA
24	21	N/a	S	+++	++	+++	R	+	3.05	NA	NA

GA indicates gestational age; aortic valve lesion: S, stenosis, A, atresia; LV dysfunction: +, mild, ++, moderate, +++, severe; EB, endocardial brightness (qualitative assessment): +, mild, ++, moderate, +++, severe; left-to-right atrial septal flow restriction: 0, none, +, mild, ++, moderate, +++, severe or intact; transverse aortic arch flow: A, antegrade, R, retrograde; mitral regurgitation (MR): 0, none, +, mild, ++, moderate, +++, severe; LV length reported as a z score (measured from the mitral annulus to the LV apex at end-diastole). Maternal-fetal patients 1 through 20 underwent attempted in utero aortic valvuloplasty. Maternal-fetal patients 21 through 24 declined the procedure. Given are fetal gestational ages and echocardiographic features at the time of diagnosis and intervention of all patients considered candidates for in utero aortic valvuloplasty.

*Achieved 2-ventricular circulation after birth.

aimed (1) to identify second- and early third-trimester fetuses with severe AS, evolving HLHS, and potentially salvageable left hearts; (2) to dilate the fetal aortic valve; and (3) to monitor the subsequent growth of left heart structures after successful fetal intervention.

Methods

Fetal Ultrasound Evaluation

Beginning in January 2000, 3 faculty echocardiographers (W.T., M.E.v.d.V., and S.D.C.) reviewed the echocardiograms based on standard fetal echocardiographic techniques^{7,13} of all midgestation fetuses with abnormal left heart structures to answer several questions: Was the dominant lesion AS; was the left heart potentially salvageable (as defined in this pilot study primarily by an LV length at the time of diagnosis not <2 SD of normal for gestational age), and was the fetus likely, in the judgment of these experts, to progress to HLHS if left untreated until term (as defined by very little antegrade flow across the aortic valve and severely depressed LV function)? This assessment was based on several case reports and small series in the literature, as well as unpublished experience from our own institution. Other variables assessed at this initial evaluation included qualitative LV function, mitral regurgitation, presence of

endocardial brightness, and characteristics of atrial septal and aortic arch flow. In utero intervention was offered to all parents whose fetus had the following echocardiographic features: AS, severe LV dysfunction, LV length that was not <2 SD below the mean for gestational age at diagnosis, left-to-right flow at the atrial septum, and retrograde flow in the transverse aortic arch (Table). No patient was refused intervention because of fetal distress (eg, severe hydrops).

Fetal Intervention

A review of previous reports from this institution and others^{7,8} suggested that when the transition from a normal-sized LV to HLHS in fetuses with AS can be documented, it almost always occurs in the second or early third trimester. Therefore, maternal-fetal management and interventional tools and techniques were geared toward the 21- to 29-week fetus, earlier in gestation than all previously reported interventions.

General anesthesia, with thiopental induction using rapid sequence techniques, intubation, and maintenance with desflurane, followed positioning with left uterine displacement and preoxygenation. Ephedrine (5-mg boluses) maintained maternal blood pressure. An injection of atropine (20 $\mu\text{g}/\text{kg}$), vecuronium (0.2 mg/kg), and fentanyl (10 $\mu\text{g}/\text{kg}$) was administered intramuscularly to the fetus for paralysis and anesthesia before passage of the cannula into the fetal

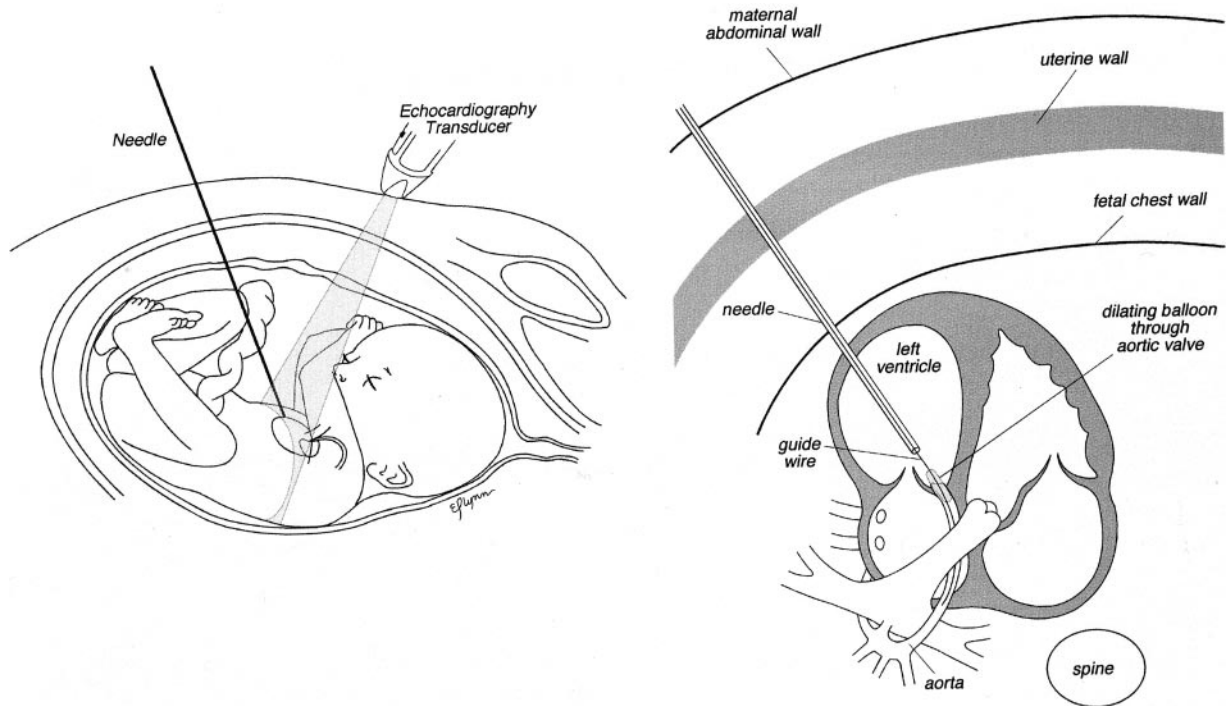


Figure 1. Ideal fetal position and cannula course. Fetal left chest is anterior, and pathway from maternal abdomen to LV apex is unobstructed. This pathway, which corresponds to cannula course, continues from LV apex to aortic valve.

chest. The techniques we used were similar to those reported previously.^{9–11,14} Under continuous ultrasound guidance, we advanced an 11.5-cm-long 19-gauge cannula and stylet needle through the maternal abdomen, uterine wall, and fetal chest wall and into the fetal LV (Figure 1). Position within the LV cavity was inferred from blood return out of the cannula and ultrasound imaging. After LV entry, we attempted to manipulate a 0.014-in coronary guidewire with a gently precurved tip across both stenotic and atretic aortic valves, again using ultrasound guidance, intending to dilate the valve with a coronary balloon 10% smaller than the aortic annulus (Figure 2).

After a high rate of technical failure in the first 4 patients, the technique was reviewed, leading to several observations. Cannula puncture of hypertensive LVs was observed to cause, in some cases, cavity shrinkage, impairing ultrasound imaging and wire manipulation. Ultrasound guidance of wire manipulation can be suboptimal; after the wire is withdrawn, rotated, and readvanced, the imaging plane must be adjusted to find the repositioned wire. The technique was therefore revised, and the following modifications were made. First, the cannula, guidewires, and balloon shafts were premeasured and marked so that positioning within the fetal heart was known from external measurements rather than the ultrasound imaging alone. The balloon shaft was marked so that no more than the full length of the balloon (1.8 cm from the tip) extruded out of the cannula tip when fully advanced, and the wire was fixed with a torque handle so that no more than 4 cm of wire extruded from the balloon tip when fully expanded. Next, fetal positioning assumed paramount importance. We did not attempt to enter the LV unless fetal positioning was nearly ideal in that the left chest was anterior, there were no limbs between the uterine wall and LV apex, the LV apex was within 9 cm of the abdominal wall, and the LV outflow track was parallel to the intended cannula course. If ideal positioning could not be obtained by external or transvaginal manipulation, the maternal abdominal wall was incised, the uterus was exposed, and fetal positioning was reattempted. The optimum ultrasound view proved to be that in which both the entire cannula length and the LV were included in the field of view. The LV was entered at the apex, with the cannula course parallel to the LV outflow track, so that a blindly advanced wire would be directed at the aortic valve, crossing the valve with minimal manipulation (Figure 2c). Balloon positioning for inflation

was based on external measurements and ultrasound imaging, and balloons were inflated with pressure gauges to allow precise estimates of inflation diameters. Small-volume-unit doses of epinephrine and atropine were available for immediate postintervention fetal intramuscular or intracardiac injection for fetal bradycardia.

Assessment of Left Heart Growth and Function After Attempted Intervention

We monitored the growth and function of the fetal and neonatal heart in all subjects, whether or not the intervention was technically successful as defined below. Follow-up echocardiograms included a qualitative assessment of LV function, growth of the left heart structures, and color Doppler flow patterns. After delivery, all infants were managed as would be standard for neonates with AS, coarctation, or HLHS.

Informed Consent

This study was performed under an innovative therapy protocol under the direction of the Committee on Clinical Investigation at the Children's Hospital Boston and the Institutional Review Board at the Brigham and Women's Hospital. In every case, the parents were counseled about fetal and maternal risks and benefits by a pediatric cardiologist, an obstetrician, a fetal surgeon, and an anesthesiologist before procedural consent was obtained.

Statistical analyses were performed by use of a paired *t* test. We compared the growth of the left heart structures (mitral annulus, aortic annulus, ascending aorta, and LV diastolic long- and short-axis dimensions and area) during gestation in the group of fetuses who had a technically successful intervention with those who had an unsuccessful intervention and those who declined the procedure. We used the first and last fetal echocardiograms during gestation to collect the left heart measurement data.

Results

Fetal Ultrasound Evaluation

Between March 1, 2000, and March 1, 2004, a total of 24 fetuses met the entry criteria noted above. In each, aortic

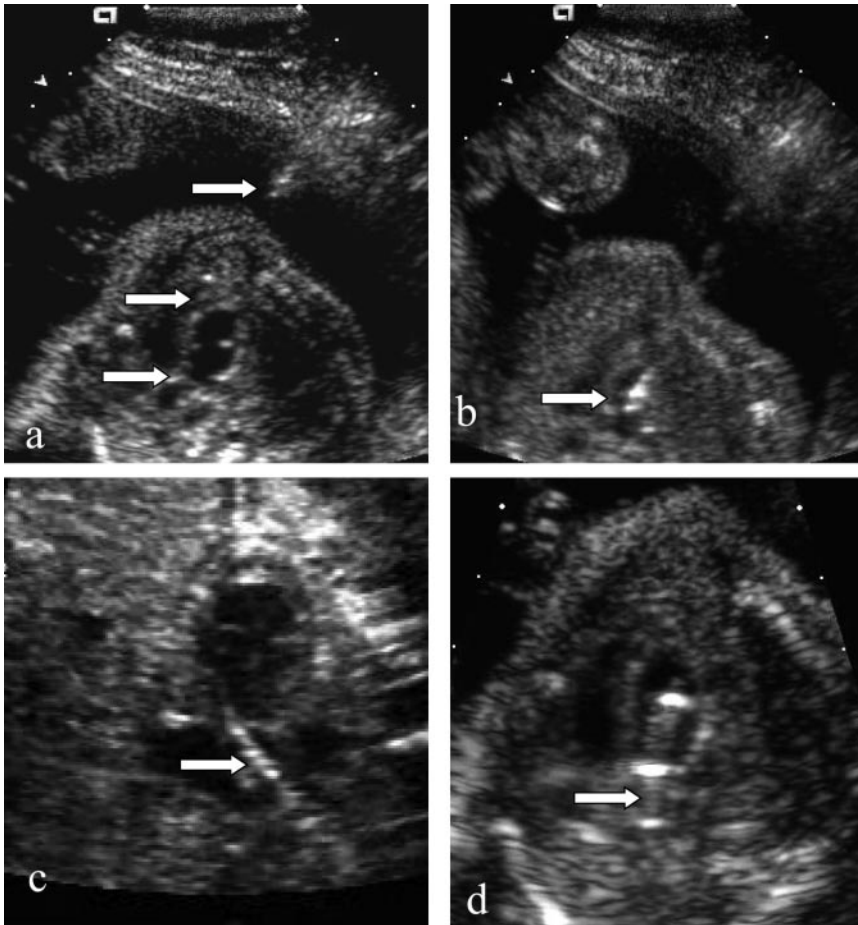


Figure 2. Ultrasound images of technically successful percutaneous in utero aortic valvuloplasty. a, LV before intervention. Four-chamber view demonstrating echogenic LV, apex-forming RV, and alignment of needle (arrow), LV apex (arrow), aortic valve, and ascending aorta (arrow). b, Cannula in LV. After LV puncture with cannula, LV appears smaller. Cannula can be seen as echo-bright line in LV, with its tip directed at aortic valve (arrow). c, Guidewire across aortic valve in ascending aorta (arrow). d, Balloon across aortic valve. Correct position of balloon across aortic valve is confirmed by external measurements of catheter and by ultrasound imaging. Balloon inflation appears as movement of bright reflection along line of LV outflow track and across level of valve (arrow).

obstruction was the dominant lesion (AS, 22; aortic atresia, 2), the fetuses were second or early third trimester at the time of diagnosis (gestational age, 17 to 26 weeks), the LV length was not <2 SD below the mean for gestational age (Figure 3), and at least 3 echocardiographers agreed that the fetus was likely to progress to HLHS if left untreated until term. Four sets of parents (4 of 24, 16%), after discussion of risks and benefits, declined further intervention. One pregnancy was terminated, and 3 infants were carried to a term delivery (all 3 had a postnatal diagnosis of HLHS). The clinical characteristics of the remaining 20 cases are summarized in the Table. Of note, 1 fetus (patient 6 in the Table) with severe AS, severe mitral regurgitation, and an intact atrial septum had developed massive LV and left atrial dilation, leading to right heart compression and severe hydrops fetalis before the procedure.

Fetal Intervention

Fetal intervention was undertaken between 1 and 6 weeks after the initial diagnosis of fetal AS. Of considerable interest, several fetuses demonstrated a progressive decrease in LV size in relation to the size of the right ventricle (RV) even during the interval between diagnosis and subsequent fetal intervention (Figure 4). As noted, 3 of the first 4 attempts were technically unsuccessful, despite successful entry of the LV with the 19-gauge cannula in all cases. Technically unsuccessful cases shared several features, including subop-

timal fetal positioning, inability to manipulate the wire across the aortic valve, and a cannula angle that directed the wire either posterior or toward the ventricular septum instead of toward the aortic valve. Of 16 subsequent patients, 13 had a

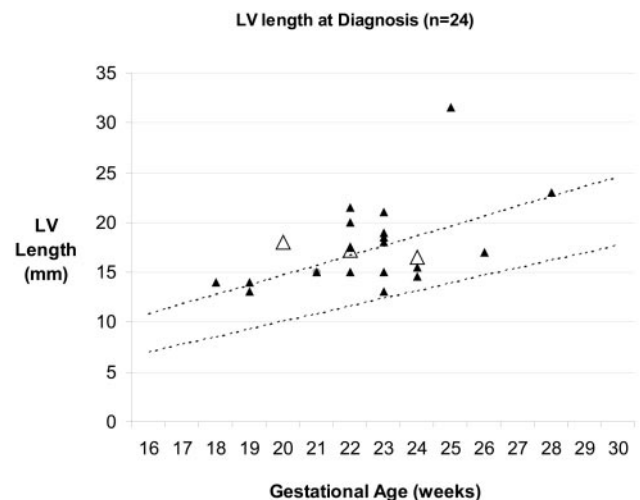


Figure 3. LV length at time of diagnosis in 24 fetuses with severe AS that were considered candidates for in utero aortic valvuloplasty. Twenty fetuses underwent attempted in utero aortic valvuloplasty (LV length was measured in 4-chamber view from mitral valve annulus to LV apex at end diastole). Dotted lines represent 2 SD from normal for LV length in diastole. Hollow triangles represent 3 patients who had biventricular repair after birth.

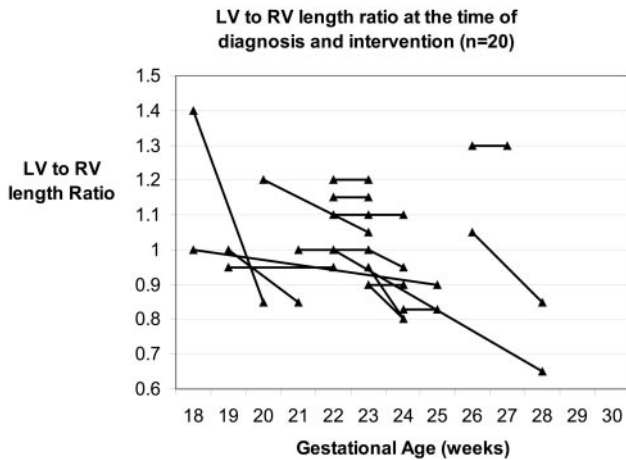


Figure 4. Ratio of LV to RV lengths between time of diagnosis of fetal AS and time of fetal intervention.

technically successful procedure in that the wire was passed across the aortic valve (including 1 case with aortic atresia), a 1-cm-long balloon was inflated straddling the valve, and there was unambiguous improvement in aortic valve flow by color Doppler. No patient among the first 8 developed more than mild aortic regurgitation, prompting us to progressively increase the balloon-to-annulus ratios during the course of the study from 0.9 to as high as 1.2. Of the 20 procedures, 10 (50%) were performed via the percutaneous route and the rest with uterine exposure via a mini-laparotomy.

Fetal complications occurred commonly during or shortly after the intervention. They included fetal demise 1 day after technically successful intervention in the fetus with severe hydrops (see above). There was a second fetal demise 1 day after an unsuccessful intervention, thought to be due to fetal stress and prolonged anesthesia time, and an additional death 3 days after the procedure in a fetus who had severe bradycardia during a technically successful dilation. That fetus also had moderate to severe mitral regurgitation. There was 1 preivable delivery as a result of incompetent cervix 3 weeks after the procedure. Interval cervical monitoring by ultrasound had been normal. Two balloons ruptured during a second or third inflation after we had repositioned the balloon more proximally. In 1 patient, a balloon fragment was missing when the balloon was removed through the cannula. Intraoperative fetal bradycardia occurred in 15 cases, requiring administration of epinephrine in 11 with recovery of normal heart rate in all. Two fetuses had a small pericardial effusion that resolved spontaneously within several hours. Maternal respiratory compromise requiring oxygen administration occurred in the patient presenting with fetal hydrops and responded to diuresis on postoperative day 1. None of the mothers experienced hemorrhage requiring blood transfusion, postoperative infection, or thrombotic events.

Assessment of Cardiac Growth and Function

In pregnancies that continued, all fetuses underwent serial postoperative echocardiograms until the time of delivery; the fetuses with a technically successful procedure were analyzed separately from those with a failed procedure and those who

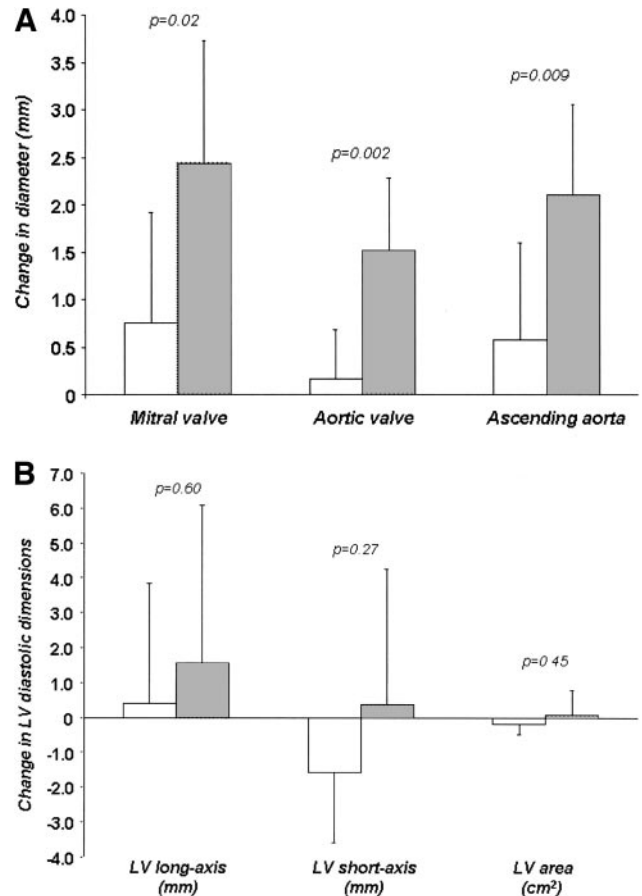


Figure 5. A, Change in dimension of left heart structures (mitral and aortic valves and ascending aorta) in fetuses that had technically successful in utero aortic valvuloplasty (gray bars) vs those with unsuccessful procedure and those that declined procedure (white bars). Only fetuses with pregnancies carried to near-term delivery (>33 weeks' gestation) were included. Data reflect first and last measurements made during gestation (n=15 for data in this figure; of original 24 patients evaluated, 3 are still in utero, 3 died in utero, 1 was born prematurely, and 2 pregnancies were terminated). B, Change in LV diastolic dimensions (long axis, short axis, and cross-sectional area) of fetuses that had technically successful in utero aortic valvuloplasty (gray bars) compared with those with unsuccessful procedure and those that declined procedure (white bars). Only fetuses with pregnancies carried to near-term delivery (>33 weeks' gestation) were included. Data reflect first and last measurements made during gestation (n=15 for data in this figure; of original 24 patients evaluated, 3 are still in utero, 3 died in utero, 1 was born prematurely, and 2 pregnancies were terminated).

declined the procedure. Figure 5A and 5B demonstrates significant growth of the mitral valve ($P=0.03$), aortic valve ($P=0.003$), and ascending aorta ($P=0.008$) and a nonsignificant trend toward LV growth in fetuses with successful valvotomies compared with unsuccessful and control cases.

At delivery, all infants were assessed through the use of previously established criteria for the diagnosis of HLHS.^{15,16} All 3 surviving infants with failed in utero procedures and 4 of 9 survivors with successful procedures had LV sizes well below the minimum for 2-ventricle survival and were managed either in Boston or at their home institution for HLHS. One neonate, who had undergone an aortic valvuloplasty at 23 weeks' gestation, had a normal-sized LV at birth and mild

Flow Chart of All Patients Evaluated for Fetal Aortic Valvuloplasty

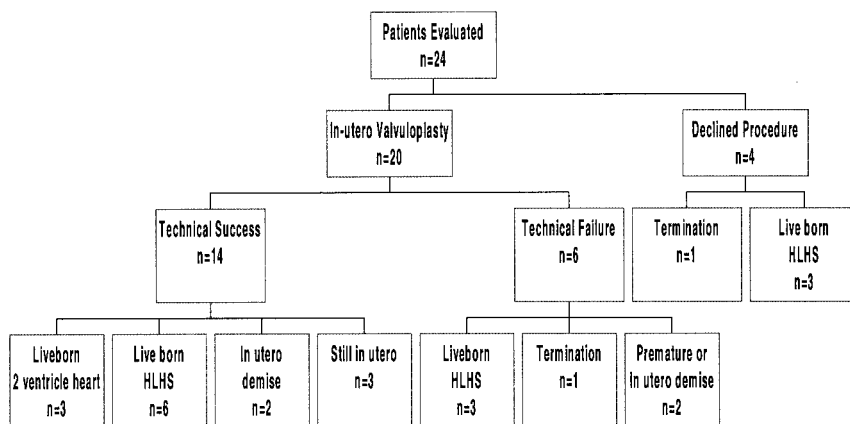


Figure 6. Flow chart showing perinatal outcomes of all 24 patients initially considered candidates for in utero aortic valvuloplasty.

AS (patient 2 in the Table). He progressed to moderate AS, underwent an uneventful AS dilation at 18 months of age, and has mild AS at 2½ years of age. Two other infants had adequate LV size at birth but significant left heart obstruction (1 with a coarctation, 1 with moderate AS; patients 14 and 16 in the Table). Both infants were treated successfully in the first week of life, and both infants were at home at 1 and 2 months of age with 2-ventricle circulation. Two infants had no AS but borderline LV sizes. Both were managed medically for 5 to 10 days to assess LV function and then underwent a Norwood procedure within 2 weeks of birth. In both cases, the atrial septum was left restrictive with the hope that there would be continued left heart growth postnatally and the potential for later biventricular repair.

Inspection of these data suggests that better in utero left heart growth may be associated with a larger preintervention LV or with features that encourage LV inflow, although the data are not sufficient to outline any predictors of success. Sustained relief of aortic obstruction also seemed to help LV growth. The statuses of all 20 fetuses are summarized in Figure 6. Three fetuses are awaiting birth.

Discussion

Since the first report of fetal cardiac intervention for severe AS appeared in 1991,⁹ 11 more cases have been reported from 10 different centers.¹¹ At present, only 2 of those 12 babies are alive; the only one who survives with a 2-ventricle circulation had intervention near term (33 weeks) and had a markedly enlarged LV, making it unlikely that this fetus would have progressed from severe AS to HLHS. Thus, the hypothesis that timely and effective intervention for severe AS in utero may prevent the development of postnatal HLHS remained untested by these reports.

Despite these disappointing initial results, we elected to revisit this problem in 2000 for several reasons. First, increased fetal cardiac surveillance has supported the thesis that severe AS in utero often presents at 19 to 23 weeks with a dilated LV but then progresses to HLHS as myocardial damage ensues and flow is diverted from the left to the right heart. In addition, improvements in angioplasty equipment, ultrasound imaging, and maternal-fetal management seemed likely to make the procedure safer and more successful.

This protocol sought to answer 3 questions: Can echocardiography identify fetuses with potentially salvageable LVs that would otherwise present with HLHS at term; can procedures be performed with relative safety and success; and does a successful procedure promote left heart growth in utero? This study provided several positive answers to each of these questions, thereby encouraging a more rigorous and extensive approach to this problem.

Identification of Suitable Candidates

The relatively loose entry criteria for this innovative therapy study produced fetal intervention in patients with heterogeneous cardiac anatomy. Nonetheless, all had severe AS or atresia as the dominant lesion with severe LV dysfunction, and all had an LV length that was not <2 SD below the mean for gestational age at diagnosis. However, some patients had dilated LVs; some had smaller LVs with endocardial brightening; some had restrictive atrial septa; some had freely patent atrial septa; some had mitral regurgitation; 1 had sub-AS that progressed to atresia during observation; and 1 had severe hydrops fetalis. Most importantly, all had a high probability to have HLHS at birth if left untreated. Finally, the timing of intervention appears to be critical. Therefore, a heightened awareness among fetal ultrasonographers of the availability of this technique will increase the number of potential candidates; once a decision to intervene is made, we view this procedure as urgent because of the rapid progression to LV growth failure.

Technique of Fetal Aortic Valvuloplasty

From these preliminary data, it is clear that several current and future technical modifications are needed for this procedure to be safe and reliable. Wire passage across the aortic valve should be quick (to avoid progressive fetal bradycardia) and nearly automatic (to reduce imaging time and the need to manipulate wires and catheters in a collapsed LV). To that end, optimum fetal positioning and angle of cannula entry are indispensable features of a successful fetal aortic valvuloplasty. Improved cannula, catheter, and wire configurations and marking techniques, more precise fetal positioning, and higher-definition 2D and/or 3D ultrasound imaging will undoubtedly improve procedural safety and success. Even in

the absence of these modifications, our last 16 cases resulted in a successful procedure in 81% of 21- to 26-week fetuses.

Changes in Fetal Cardiac Anatomy and Flow After Successful Intervention

The procedure was unsuccessful or parents declined intervention in 10 fetuses; in all, there was minimal further growth in left heart structures. In contrast, all 12 fetuses that survived a technically successful procedure experienced mitral and aortic growth. Admittedly, only 3 of 9 fetuses that had a technically successful valvotomy and a continuing pregnancy went on to a 2-ventricle circulation at birth, but these successful patients would seem to be an important proof of the underlying principle. (Three fetuses are still in utero.) Although these data support the hypothesis that HLHS is preventable in utero, improvements in patient identification, patient selection, timing of intervention, and valvuloplasty technique are needed to make this procedure biologically successful in most fetuses with severe AS.

Acknowledgments

This study was funded by the Burnes Family Research Endowment and the Marram and Carpenter Fund.

References

1. Harh JY, Paul MH, Gallen WJ, et al. Experimental production of hypoplastic left heart syndrome in the chick embryo. *Am J Cardiol.* 1973;31:51–56.
2. Hogers B, DeRuiter MC, Gittenberger-de Groot AC, et al. Unilateral vitelline vein ligation alters intracardiac blood flow patterns and morphogenesis in the chick embryo. *Circ Res.* 1997;80:473–481.
3. Hove JR, Koster RW, Forouhar AS, et al. Intracardiac fluid forces are an essential epigenetic factor for embryonic cardiogenesis. *Nature.* 2003;9:421:172–177.
4. Hawkins JA, Clark EB, Doty DB. Morphologic characteristics of aortic atresia: implications for fetal hemodynamics. *Int J Cardiol.* 1986;10:127–132.
5. Sedmera D, Hu N, Weiss KM, et al. Cellular changes in experimental left heart hypoplasia. *Anat Rec.* 2002;1:267:137–145.
6. Danford DA, Cronican P. Hypoplastic left heart syndrome: progression of left ventricular dilation and dysfunction to left ventricular hypoplasia in utero. *Am Heart J.* 1992;123:1712–1713.
7. Hornberger LK, Sanders SP, Rein AJ, et al. Left heart obstructive lesions and left ventricular growth in the midtrimester fetus: a longitudinal study. *Circulation.* 1995;92:1531–1538.
8. Simpson JM, Sharland GK. Natural history and outcome of aortic stenosis diagnosed prenatally. *Heart.* 1997;77:205–210.
9. Maxwell D, Allan L, Tynan MJ. Balloon dilatation of the aortic valve in the fetus: a report of two cases. *Br Heart J.* 1991;65:256–258.
10. Lopes LM, Cha SC, Kajita LJ, et al. Balloon dilatation of the aortic valve in the fetus: a case report. *Fetal Diagn Ther.* 1996;11:296–300.
11. Kohl T, Sharland G, Allan LD, et al. World experience of percutaneous ultrasound-guided balloon valvuloplasty in human fetuses with severe aortic valve obstruction. *Am J Cardiol.* 2000;85:1230–1233. Review.
12. Harrison MR. Surgically correctable fetal disease. *Am J Surg.* 2000;180:335–342. Review.
13. Tworetzky W, McElhinney DB, Reddy VM, et al. Improved surgical outcome after fetal diagnosis of hypoplastic left heart syndrome. *Circulation.* 2001;103:1269–1273.
14. Myers LB, Cohen D, Galinkin J, et al. Anaesthesia for fetal surgery. *Paediatr Anaesth.* 2002;12:569–578. Review.
15. Rhodes LA, Colan SD, Perry SB, et al. Predictors of survival in neonates with critical aortic stenosis [published erratum appears in *Circulation.* 1995;92:2005]. *Circulation.* 1991;84:2325–2335.
16. Schwartz ML, Gauvreau K, Geva T. Predictors of outcome of biventricular repair in infants with multiple left heart obstructive lesions. *Circulation.* 2001;104:682–687.