



Thumb Hypoplasia and Aplasia

What is thumb hypoplasia and aplasia?

Thumb **hypoplasia**, also commonly called hypoplastic thumb, means that your child's thumb is unusually small or underdeveloped.

Thumb **aplasia** means that your child's thumb is missing altogether.

What causes an underdeveloped or missing thumb?

The cause of this condition is unknown. However, it often happens together with radial longitudinal deficiency (radial club hand). It can also happen in association with Holt-Oram and Fanconi syndromes and VACTERL sequence.

How is it diagnosed?

Thumb hypoplasia and aplasia are usually seen during your baby's first newborn exam. Your child's doctor will look for other deformities that are sometimes associated with this condition. Your child may have an X-ray to look at the structures of your child's thumb. Other tests will depend on whether the doctor suspects another condition.

What are the types of thumb hypoplasia and aplasia?

Type 1 Your child's thumb is slightly smaller than normal, but all of its structures – the bones, tendons, ligaments, muscles and joints are normal. Surgery is not typically needed.

Type 2 Your child's thumb is small and there are often minor abnormalities in the tendons and muscles within the thumb. The middle joint of the thumb is unstable, causing the thumb to wobble. The web space between the thumb and index finger is tight and limits movement. The bones of your child's thumb are small. Thumb reconstruction surgery may be recommended to improve the strength of the thumb.

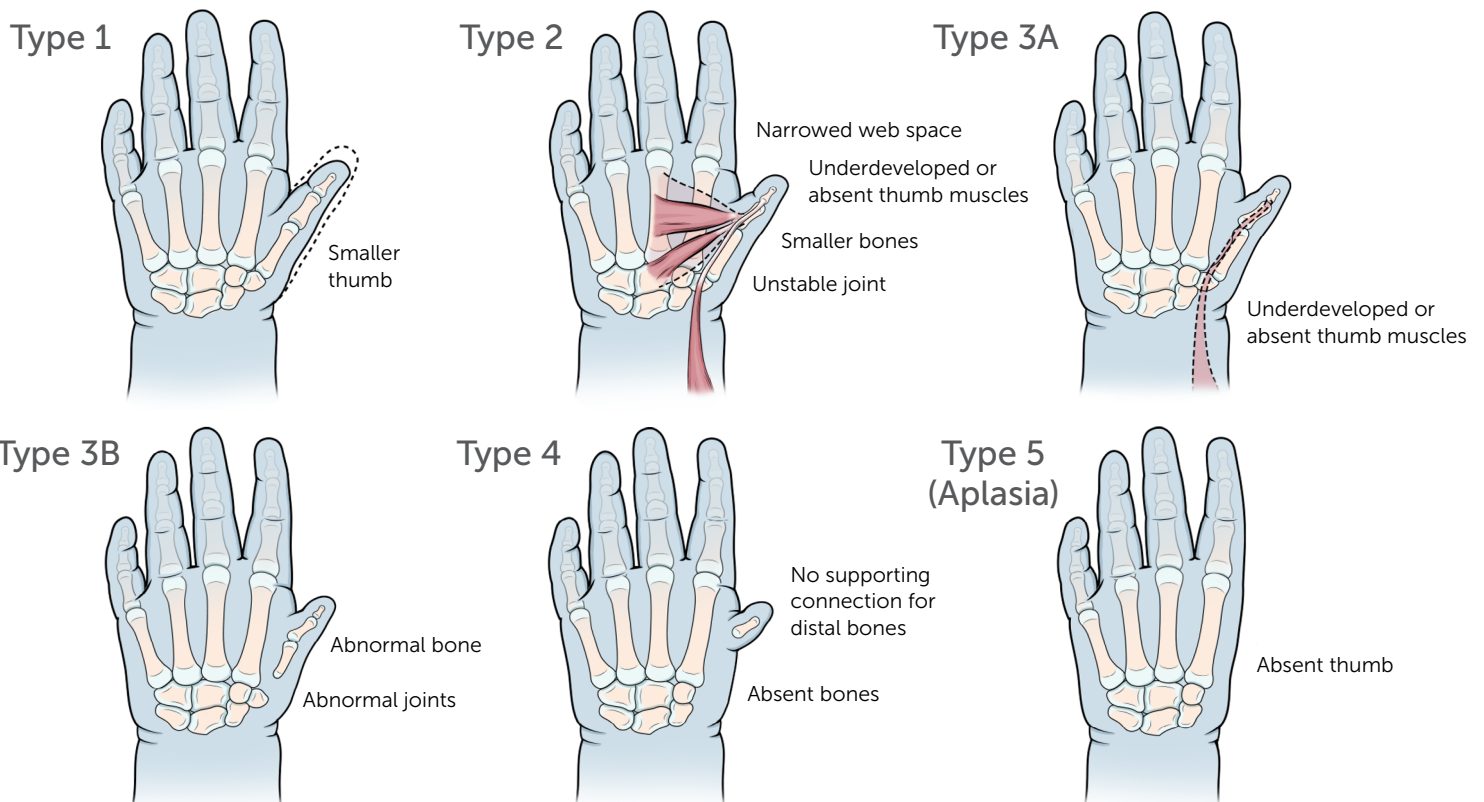
Type 3 The bones of your child's thumb are small. There are abnormalities in many or all of the muscles of the thumb along with a range of problems in the joints of the thumb and an abnormal tight web space between their thumb and index finger. Either a thumb reconstruction or index pollicization is generally recommended depending on the stability of the thumb.

Type 4 Your child's thumb is "floating" with no bony support and is attached to the hand by only skin and soft tissue. Index pollicization surgery is generally recommended.

Type 5 Your child's thumb is missing. Index pollicization surgery may be recommended.

How is it treated?

Children adapt and can function with a missing finger. If untreated, children who have no use of a thumb can learn to pinch using their long and index fingers. But they may have problems with pinch strength as well as activities that require holding a larger object. Surgeries for thumb hypoplasia are designed to help with these issues. However, the decision about whether or not thumb hypoplasia/aplasia should be treated is not always straightforward.



Here is a general description of treatment options that your child's doctor will discuss with you:

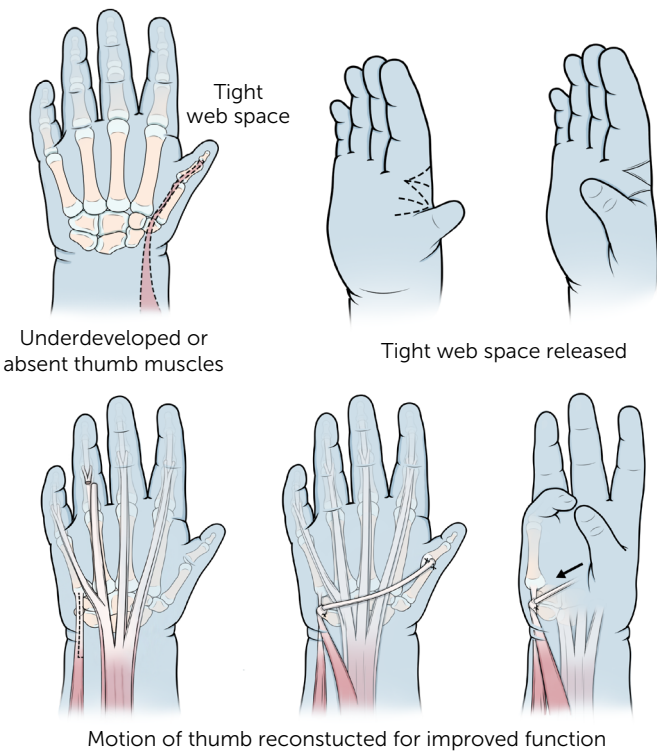
Occupational therapy

This is an option if your child has a mild case of thumb hypoplasia and their thumb is slightly shorter and/or weaker, or if the web space between the thumb and index finger is slightly tighter than normal. For more severe cases in which surgery is recommended, Occupational Therapy after surgery is essential to maximize results.

Surgery - Thumb reconstruction

This may involve an operation to release the tight web space between the thumb and index finger using skin graft, stabilize the middle joint through ligament reconstruction and improve function and stability by transferring a tendon from another part of the hand.

Thumb Reconstruction



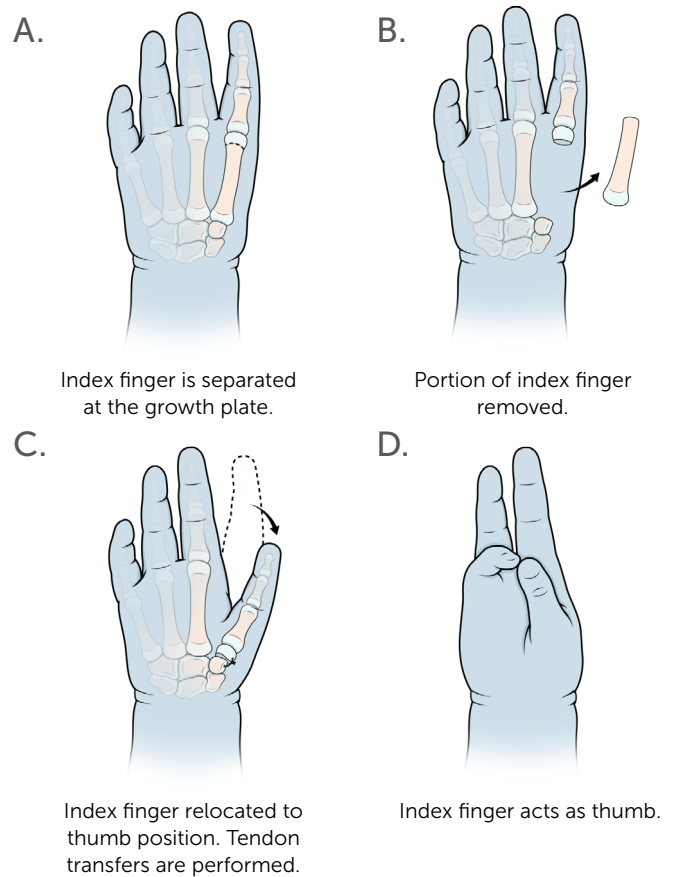
Surgery - Index pollicization

This may be an option if your child has no thumb or when the hypoplasia is more severe. The operation involves creating a functional thumb by transferring another finger (usually the index) to the thumb position.

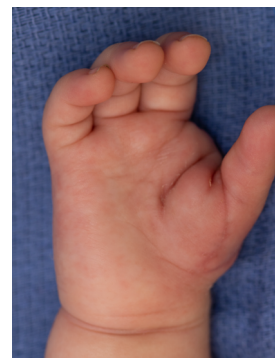If there are no other pressing medical concerns that need to be addressed, pollicization surgery is generally performed when your child is between 6–18 months old. Thumb reconstruction can be done as early as 1 year, up through school-age.

After surgery or occupational therapy, your child's thumb should function very well, although some differences in strength and appearance are common.

Index Pollicization



Notes



Hand after Index Pollicization surgery