



Madelung's Deformity

What is Madelung's deformity?

Madelung's deformity is a rare arm condition that affects the growth plate of the radius. This results in an abnormality of the wrist alignment where the 2 long bones of the forearm (the radius and ulna) meet the carpal bones of the wrist.

It is a congenital condition, meaning that your child was born with it. But it often does not show up until children go through their pre-adolescent growth spurt.

The condition usually affects both of a child's wrists, but the severity may be different between the two sides.

What causes Madelung's deformity?

The exact cause is unknown. It may be due to an abnormal growth plate at the end of the radius and/or an abnormal ligament connecting the end of the radius to the small bones of the wrist.

Sometimes, a trauma or injury to the growth plate at the end of the radius may cause a deformity similar to Madelung's.

Girls are more often affected than boys. Researchers believe that this is probably due to mutation in a gene on the X chromosome.

It can be associated with certain genetic syndromes, such as Leri-Weill dyschondrosteosis, Turner syndrome, and nail-patella syndrome.

How is Madelung's deformity diagnosed?

The condition is usually diagnosed when a child is between 8–14 years old, but sometimes it is seen and diagnosed earlier. Your child will probably have a physical exam and X-rays. They may have other testing and/or referral to a geneticist if the doctor suspects an associated syndrome.

How is Madelung's deformity treated?

Many children have no pain or limitations, and do not need treatment. Your child's doctor will probably recommend that you bring them in regularly so doctors can monitor the condition as your child grows.

If your child has pain, trouble using their wrist, or if the deformity gets worse, your doctor may recommend surgery.

In general, the goals of surgery are to reposition and stabilize your child's wrist so they can move it without pain. Surgery also aims to prevent the deformity from getting worse.

The type of surgery depends on your child's age and general health, how severe the deformity is and how well your child can move and use their wrist.

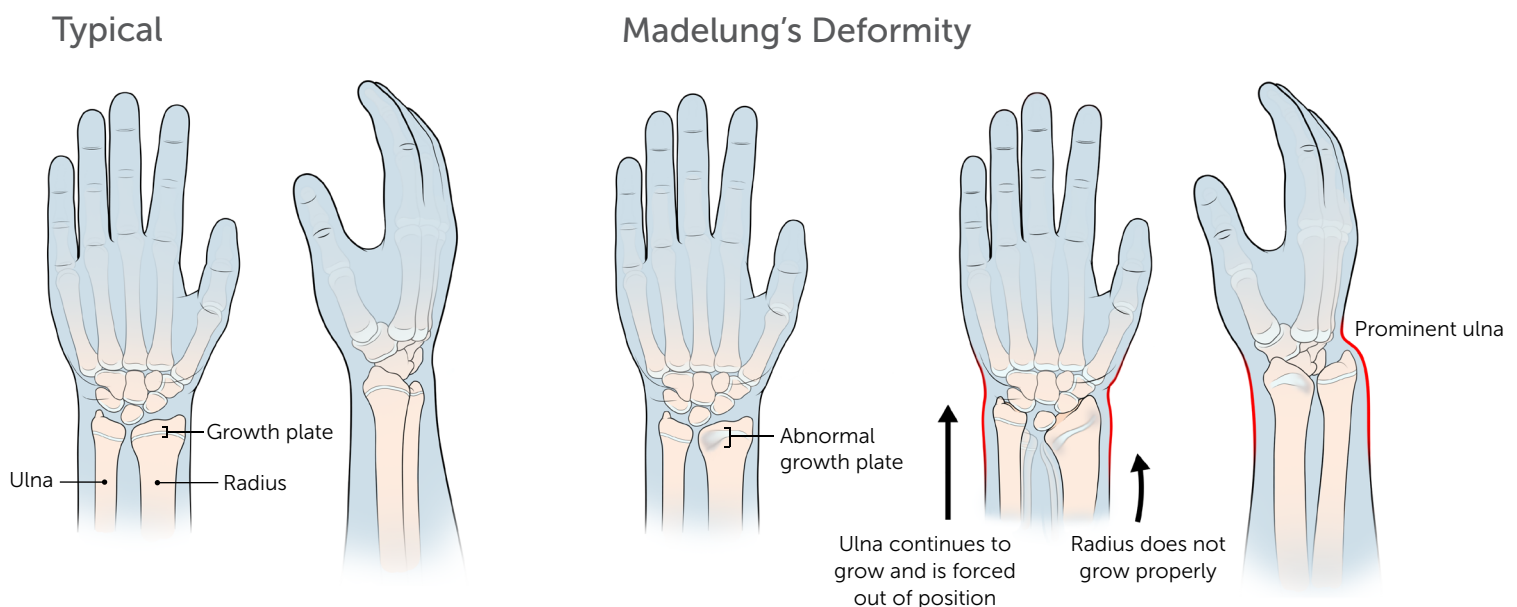
Physiolysis Releasing or correcting the growth plate abnormality of the radius to prevent worsening of the wrist deformity in young children.

Dome osteotomy of the wrist Cutting and realigning the end of the radius so that it can better support the small bones of the wrist.

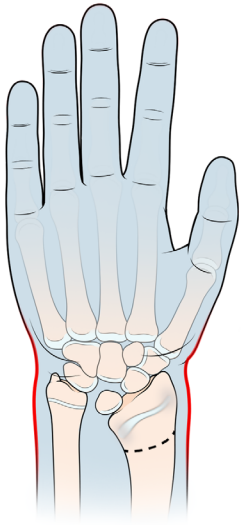
Ulnar-shortening osteotomy Shortening the ulna bone to level the wrist. This can be done as a stand-alone procedure, or at the same time as a radius osteotomy.

Darrach procedure Removing the part of the ulna that is sticking out. This is rarely performed in young patients.

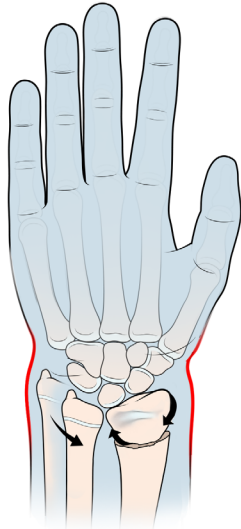
Wrist arthroscopy A camera is inserted in the wrist to evaluate and treat any cartilage injury within the wrist joint that may have been caused by the abnormal alignment of the wrist. Wrist arthroscopy is typically performed in conjunction with other procedures for Madelung's.



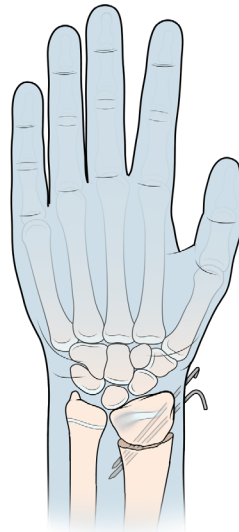
Osteotomy Procedure



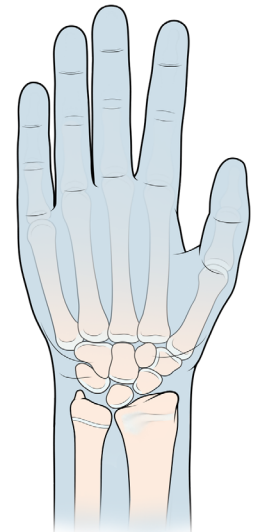
The radius is cut.



The radius is rotated into a more ideal position.



Pins hold the bone in place while it heals.



Radius heals in its proper position.

Notes

