

# Nasal Dermoid Sinus Cysts

## *A Retrospective Review and Discussion of Investigation and Management*

*Will E. Blake, MBBS, C. W. Chow, FRCPA, Anthony D. Holmes, FRACS,  
and John G. Meara, MBA, FRACS*

**Abstract:** Nasal dermoid sinus cysts are uncommon congenital anomalies presenting either as cysts or sinuses. They are frequently associated with extension into the intracranial space, requiring craniotomy for adequate resection. At the Royal Children's Hospital in Melbourne, Australia, we have managed 25 patients with nasal dermoid sinus cysts over 8 years and present details of clinical features, preoperative assessment, and surgical management. Six patients presented with infection, including 1 with osteomyelitis. Four of our patients had intracranial extension of their lesions, and all were treated successfully with tailored investigation and appropriate surgical procedures. Insights into diagnosis, investigation, and surgery are offered to facilitate the management of these challenging lesions.

**Key Words:** nasal dermoid sinus cysts, nasal dermoid, nasal sinus, nasal cyst, congenital midline mass

*(Ann Plast Surg 2006;57: 535–540)*

Nasal dermoid sinus cysts are an uncommon midline anomaly with an embryologic origin quite distinct from dermoids elsewhere on the face and requiring an especially careful approach to management. They are congenital lesions lined by stratified squamous epithelium, with normal dermal appendages, including hairs and sebaceous glands (Figs. 1–3). Some debate about the origin of these lesions exists, but they are thought to arise in the early embryonic period, during closure of the anterior neuropore, during development of the frontonasal process or during closure of the fonticulus nasofrontalis (a potential defect between the developing frontal and nasal bones).<sup>1,2</sup>

Received January 16, 2006, and accepted for publication, after revision, May 3, 2006.

From the Department of Plastic and Maxillofacial Surgery and Department of Pathology, Royal Children's Hospital, Melbourne, Australia.

Reprints: John G. Meara, MBA, FRACS, Department of Plastic Surgery, Royal Children's Hospital, Flemington Rd, Melbourne, Victoria 3052, Australia. E-mail: john.meara@rch.org.au.

Copyright © 2006 by Lippincott Williams & Wilkins

ISSN: 0148-7043/06/5705-0535

DOI: 10.1097/01.sap.0000229060.20055.07

Regardless of the embryology, the lesions may present in a variety of ways: as a cystic mass or as a sinus opening onto the midline dorsum of the nose between the glabella and the columella. Commonly, the sinus will discharge cheesy offensive material or grow abnormal hairs. Both cysts and sinuses may have a connection with an intracranial component through an abnormal foramen cecum in the anterior cranial fossa. Such connections are not usually apparent on clinical examination.

The differential diagnosis needs to be carefully considered during assessment and includes ectopic neuroglia, encephaloceles, and teratomas. Common epidermoid cysts, lined by a squamous epithelium without appendages, may also uncommonly occur in the midline. The differential diagnosis and embryology have been extensively reviewed elsewhere.<sup>3</sup>

Because of the frequent association with tracts or sinuses connecting nasal dermoid sinus cysts to the skull base or the anterior cranial fossa, much consideration must be given to tailoring management to the individual patient. We have reviewed our experience with this condition in the hope of clarifying the best approach to investigation and surgical planning and to avoiding pitfalls.

### PATIENTS AND METHODS

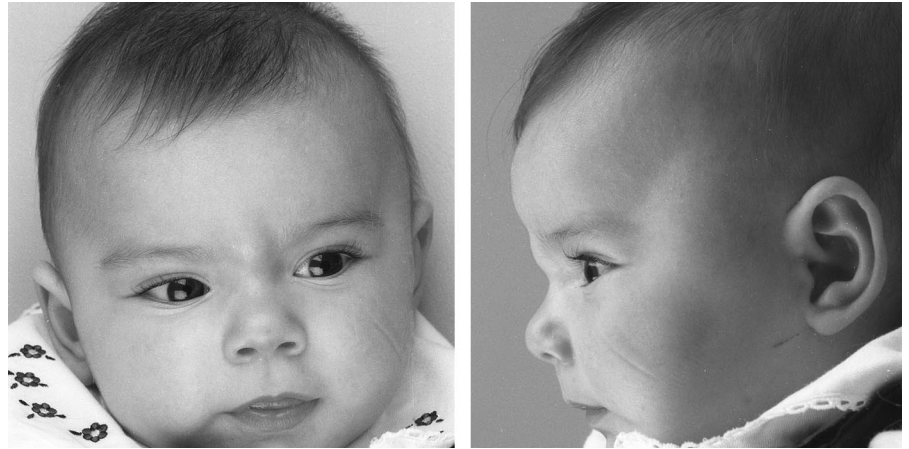A retrospective analysis of all admissions to the Royal Children's Hospital, Melbourne, Australia, for the period January 1997 to October 2005 was undertaken to identify those patients with a discharge diagnosis of nasal dermoid cyst or dermoid sinus. Data were collected from radiology and pathology archives to ensure that the diagnosis of nasal dermoid sinus cyst was proven.

Twenty-eight patients were identified, and, of these, 25 were suitable for inclusion in this series. Three patients were excluded because their histology results did not confirm the diagnosis of nasal dermoid sinus cyst.

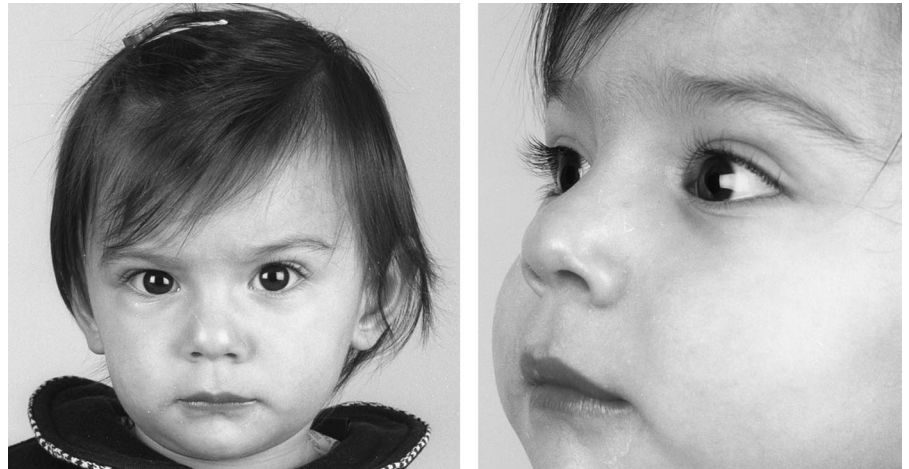Details of the patients, their presentation, and management are included in Table 1.

### RESULTS

Of the 25 patients with nasal dermoid sinus cysts, the age at the time of surgery varied from 6 months to 8 years. There were 15 boys and 10 girls. Presenting complaints



**FIGURE 1.** Nasal dermoid sinus cyst before endoscopic removal.

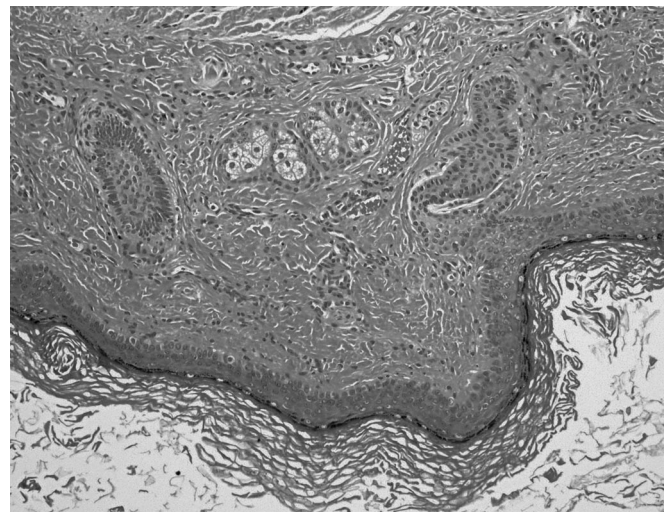


**FIGURE 2.** Nasal dermoid sinus cyst after endoscopic removal. The cyst is midline and, in this patient, not associated with a punctum or sinus. CT and MRI revealed no evidence of intracranial extension.

included a lump in all patients and previous or current infection in 6 patients. A sinus was the cause of presentation in 2 patients and was clearly present on initial assessment in a further 5. Several patients described previous cheesy discharge.

All patients had preoperative investigations, although these were not available for analysis in one case. Computed tomography (CT) and magnetic resonance imaging (MRI) were both available throughout the study period. Thirteen patients had both a CT and an MRI (Fig. 4). Seven patients had a CT only, and 4 patients had an MRI only. One patient with a history of previous infection had an ultrasound in the preoperative period. Table 2 presents the results of investigations and correlates these with subsequent surgical findings.

Preoperative investigation revealed or suggested intracranial extension in 5 patients. These 5 underwent combined management with a neurosurgeon and a plastic surgeon. Of these 5 patients, 4 required anterior craniotomy, while in one case the dermoid sinus was traced to its conclusion at but not beyond the foramen cecum and a craniotomy was not necessary. In this patient the preoperative MRI had allowed the radiologist to make precisely this conclusion, while the CT was suggestive of intracranial extension.



**FIGURE 3.** Typical section of a nasal dermoid sinus cyst displaying a stratified squamous epithelium with hair follicles and sebaceous glands. Hematoxylin and eosin  $\times 100$ .

**TABLE 1.** Patient Demographics and Management

Patient	Age, Year	Gender	Presentation	I/C	Operation	Investigation	Complications
1	1.1	M	Infected lump	Yes	Anterior craniotomy	MRI	Recurrence
2	1.2	M	Lump	Yes	Anterior craniotomy	CT/MRI	
3	0.4	M	Lump	Yes	Anterior craniotomy	CT/MRI	
4	7.3	M	Lump, sinus	Yes	Anterior craniotomy	CT	Scar revision 3 years postop
5	1.6	M	Lump, discharge, osteomyelitis	No	Coronal approach	CT/MRI	
6	2.0	F	Lump	No	Direct excision	CT/MRI	
7	5.5	M	Lump	No	Direct excision	CT/MRI	
8	0.8	F	Lump	No	Direct excision	CT/MRI	
9	0.8	F	Lump	No	Direct excision	CT	
10	1.6	F	Lump	No	Direct excision	CT	
11	1.9	F	Lump	No	Direct excision	CT	
12	3.2	F	Lump	No	Direct excision	CT	
13	7.6	M	Lump, prior infection	No	Direct excision	CT/MRI/US	
14	1.6	M	Lump, sinus	No	Direct excision	MRI	
15	1.2	M	Lump, sinus	No	Direct excision	MRI	
16	2.9	M	Lump, sinus, prior infection	No	Direct excision	CT/MRI	Superficial wound infection
1	3.0	M	Recurrent lump	No	Direct excision	CT	
17	3.3	F	Recurrent lump*	No	Direct excision	CT/MRI	
18	3.2	M	Lump	No	Direct excision and open rhinoplasty	CT/MRI	
19	7.0	F	Lump, sinus	No	Direct excision and open rhinoplasty	CT/MRI	
20	3.5	M	Sinus, prior infection	No	Direct excision and open rhinoplasty	CT	Nasal obstruction
21	2.3	M	Lump	No	Endoscopic excision	†	
22	0.5	F	Lump	No	Endoscopic excision	CT	
23	8.4	F	Lump	No	Endoscopic excision	CT/MRI	
24	7.0	M	Lump, discharge	No	Open rhinoplasty	CT/MRI	
25	1.4	M	Lump, sinus, prior infection	No	Open rhinoplasty	MRI	Nasal obstruction

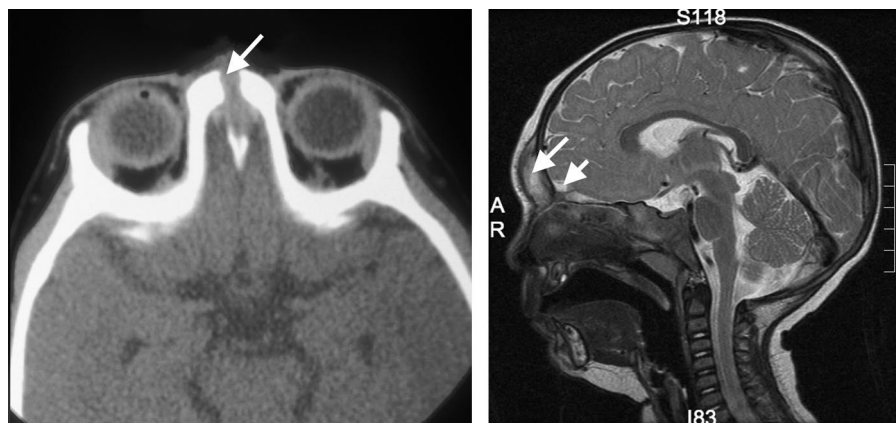
CT, computed tomography; F, female; M, male; I/C, intracranial; MRI, magnetic resonance imaging; US, ultrasound.

\*Patient with recurrence previously treated elsewhere.

†Investigation undertaken elsewhere and not available.

The 25 patients underwent 26 operative procedures for excision. Surgical approaches included a bicoronal incision for craniotomy (5 patients), excision and direct closure (16 patients, including 3 who had an open rhino-

plasty also), open rhinoplasty only (2 patients), and an endoscopic approach (3 patients). The patients undergoing craniotomy also required an open excision of their nasal lesion (Fig. 5).



**FIGURE 4.** Classic appearance of nasal dermoid sinus cyst with intracranial extension. CT (left) shows a defect in the nasal bone (arrow) in the midline and bifid crista galli, while MRI (right) shows an enhancing lesion in the anterior cranial fossa and subcutaneously (arrows). T2 sagittal image.

**TABLE 2.** Preoperative Investigation Results Stratified by Final Surgical Diagnosis

Radiology Report	Patients With Intracranial Disease at Surgery, n = 4	Patients With No Intracranial Disease at Surgery, n = 21
CT result		
Intracranial		1
Uncertain	2	
Superficial	1	16
MRI result		
Intracranial	2	
Uncertain	1	2
Superficial		12

Intracranial, intracranial disease demonstrated in this investigation; uncertain, no clear opinion offered in the report of this investigation regarding intracranial extension; superficial, superficial only, no intracranial extension demonstrated.

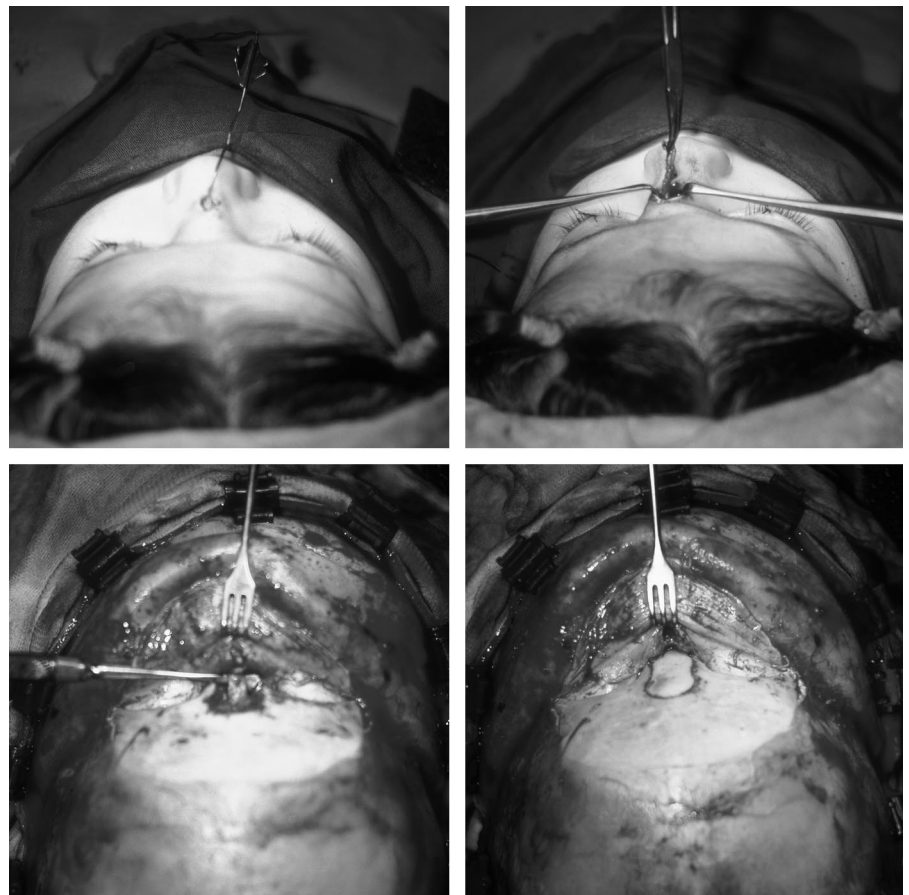
Postoperative complications were 1 recurrence in a patient with intracranial disease who required reoperation, 1 wound infection, and 1 patient requiring scar revision. Two patients described nasal obstruction in the postoperative period, but this settled spontaneously, and neither required surgical intervention.

**DISCUSSION**

A clear understanding of several features of nasal dermoid sinus cysts is critical to the diagnosis and management of this condition. First, there is a significant rate of spontaneous infection, as evidenced by the 6 patients in our cohort presenting with prior or current infection. One individual required prolonged intravenous antibiotic therapy to treat frontal bone osteomyelitis. Other spontaneous complications of these lesions before treatment include discharge, aberrant hair growth, and an enlarging unsightly mass distorting nasal growth.

Presented with the need for excision, the next consideration is how to best establish the true extent of the lesion so that an appropriate surgical plan is developed. The objective of imaging studies is to confirm the clinical diagnosis and to delineate any intracranial involvement if present. Our 25 patients had 37 preoperative CT and MRI examinations, which are presented in Table 2. Our series of CT scans contained both false-negative and false-positive results. MRI produced no incorrect results, although 3 studies were non-diagnostic due to movement artifact.

The complementary roles of CT and MRI appear well established in congenital midline nasal masses.<sup>4-6</sup> Bony detail is best defined by CT, while MRI images soft tissues



**FIGURE 5.** Intraoperative photographs on nasal sinus with intracranial extension. Top left, A lacrimal probe sits in the cutaneous opening of the sinus. Top right, The nasal part of the sinus is excised. Lower left, Coronal approach reveals the intracranial extension. Lower right, A small anterior craniotomy allows complete resection.

more precisely. Many children will require general anesthesia for adequate MRI evaluation, and the invasiveness of this procedure has been justified by improved planning by several authors.<sup>4,5,7</sup> Some maintain, however, that CT provides all the information required and that certain specific findings can reliably and specifically diagnose intracranial extension.<sup>8</sup> Based on this review, it is felt that CT and MRI do have complementary roles in preoperative evaluation, and on one occasion in our study population, a CT scan was associated with an incorrect conclusion that no intracranial extension existed where in fact such a connection did exist.

Surgical approaches to the removal of nasal dermoid sinus cysts can be entirely extracranial or require a craniotomy. In our study, a variety of extracranial techniques were employed. Excision and direct primary closure is the most straightforward and has the advantage of removing abnormal skin overlying a cyst or the opening of a sinus. Incisional wounds, particularly those oriented vertically, are well tolerated. Surgical scars generally settle well, and the surgeon has an opportunity to remove dysplastic or stretched skin over a sinus. Open rhinoplasty, either alone or combined with a direct excision, offers the opportunity to correct the position of the alar cartilages, which are often splayed by a lesion at the nasal tip.<sup>9,10</sup> A sinus tract may be followed to the nasofrontal suture via an open rhinoplasty. Endoscopic approaches are useful for superficial lesions with no extension that lie in the glabellar region. The need for an exposed scar is avoided.

A craniotomy is required to remove a dermoid with intracranial extension. Various techniques have been described, removing all or part of the frontal bones via a coronal<sup>11,12</sup> or subcranial approach.<sup>13</sup> The technique used in this series was a coronal flap combined with a bifrontal craniotomy to approach the intracranial component and a direct excision for the subcutaneous cyst or sinus. In one patient, debridement of necrotic, infected frontal bone was required to eliminate chronic osteomyelitis. This resolved successfully with antibiotics in the postoperative period.

Among our 25 patients were 4 (16%) with intracranial extension of their nasal dermoid sinus cysts. This broadly agrees with the literature review undertaken by Hanikeri et al,<sup>14</sup> where 48 cases with intracranial extension were noted from a total of 245 reported cases (19.6%). In published reports, the proportion with intracranial extension varies widely, from 6%<sup>15</sup> to 45%.<sup>16</sup>

Few details exist in the literature about the rate of recurrence and other complications after treating nasal dermoid sinus cysts. In our series, 1 patient underwent a second operation for recurrence of the superficial component of a dermoid initially treated with a combined intra- and extracranial approach. A second patient was treated at our center for recurrence of a superficial dermoid with no intracranial extension, initially treated elsewhere. This suggests a recurrence rate of 1:24, or 4%, in our patient group, slightly less than the 12% reported elsewhere with longer follow-up.<sup>7</sup> Meticulous complete excision should prevent recurrence but is exceptionally difficult in the presence of infection.

Few other surgical complications occurred in our series. One patient had a superficial wound infection, and 2 patients mentioned annoying nasal airway obstruction, which settled spontaneously by the time of subsequent review. Generally, surgery for removal of nasal dermoid sinus cysts was well tolerated. One of the craniotomy patients had a revision of the nasal scar 3 years after the initial excision.

Nasal dermoid sinus cysts are uncommon, and no single center has a huge experience in their management. No prospective data about management of these lesions have been published, and our paper has several of the same weaknesses of previous descriptions. These weaknesses, including small numbers in the study population and retrospective study design, reflect the realities of uncommon surgical problems and are unavoidable. Nevertheless, this series adds significantly to the number of cases detailed in the literature. Long-term follow-up of our patients will reveal whether further recurrences develop with time. Ongoing evaluation of developing radiologic techniques may alter our recommendations about the role of CT and MRI in these patients.

Although nasal dermoid sinus cysts are uncommon and complex lesions, they can be managed successfully with careful clinical assessment, preoperative MRI and CT scans, and appropriate surgery. A minority of these patients will have intracranial extension, and the importance of preoperative CT combined with MRI is highlighted in our study to confirm the anatomy prior to surgery. Tailored definitive surgery, addressing defined pathology and anatomy, allows successful treatment with a low recurrence rate and few other complications.

## REFERENCES

- Charrier J-B, Rouillon I, Roger G, et al. Craniofacial dermoids: an embryological theory unifying nasal dermoid sinus cysts. *Cleft Palate Craniofac J*. 2005;42:51-57.
- Pratt LW. Midline cysts of the nasal dorsum: embryologic origin and treatment. *Laryngoscope*. 1965;75:968-980.
- Hughes GB, Sharpino G, Hunt W, et al. Management of the congenital nasal midline mass. *Head Neck Surg*. 1980;2:222-233.
- Bloom DC, Carvalho DS, Dory C, et al. Imaging and surgical approach of nasal dermoids. *Int J Paediatr Otorhinolaryngol*. 2002; 62:111-122.
- Schlosser RJ, Faust RA, Phillips CD, et al. Three-dimensional computed tomography of congenital nasal anomalies. *Int J Paediatr Otorhinolaryngol*. 2002;65:125-131.
- Huisman TA, Schneider JF, Martin-Fiori E, et al. Developmental nasal midline masses in children: neuroradiological evaluation. *Eur Radiol*. 2004;14:243-249.
- Rahbar R, Shah P, Mulliken JB, et al. The presentation and management of nasal dermoid: a 30 year experience. *Arch Otolaryngol Head Neck Surg*. 2003;129:464-471.
- Posnick JC, Bortoluzzi P, Armstrong DC, et al. Intracranial nasal dermoid sinus cysts: computed tomographic scan findings and surgical results. *Plast Reconstr Surg*. 1994;93:745-754.
- Rohrich RJ, Lowe JB, Schwartz MR. The role of open rhinoplasty in management of nasal dermoid cysts. *Plast Reconstr Surg*. 1999;104: 2163-2171.
- Bilkay U, Gundogan H, Ozek C, et al. Nasal dermoid sinus cysts and the role of open rhinoplasty. *Ann Plast Surg*. 2001;47:8-14.
- van Aalst JA, Luerssen TG, Whitehead WE, et al. "Keystone" approach for intracranial nasofrontal dermoid sinuses. *Plast Reconstr Surg*. 2005; 116:13-19.

12. Rogers GF, Proctor MR, Greene AK, et al. Frontonasal osteotomy to facilitate removal of an intracranial nasal dermoid cyst. *J Craniofac Surg.* 2005;16:731–736.
13. Kellman RM, Goyal P, Rodziewicz GS. The transglabella subcranial approach for nasal dermoids with intracranial extension. *Laryngoscope.* 2004;114:1368–1372.
14. Hanikeri M, Waterhouse N, Kirkpatrick N, et al. The management of midline transcranial nasal dermoid sinus cysts. *Br J Plast Surg.* 2005; 58:1043–1050.
15. Denoyelle F, Ducroz V, Roger G, et al. Nasal dermoid sinus cysts in children. *Laryngoscope.* 1997;107:795–800.
16. Wardinsky TD, Pagon RA, Powell BR, et al. Nasal dermoid sinus cysts: association with intracranial extension and multiple formations. *Cleft Palate Craniofac J.* 1991;28:87–95.